



**GEN KÖK**

Genom ve Kök Hücre Merkezi  
Genome and Stem Cell Center

MAKULA HASTALIKLARINDA  
SUPRAKOROİDAL MEZENKİMAL  
KÖK HÜCRE UYGULAMASI

Prof.Dr. Ayşe Öner, FEBO  
Erciyes Üniversitesi Tıp Fakültesi  
Göz Hastalıkları AD KAYSERİ  
KAYSERİ





# AMAÇ

- \* Kuru tip yaşa bađlı makula dejenerasyonlu 4 olgu
- \* Stargardt makula distrofili 3 olgu
- \* Suprakoroidal mezenkimal kök hücre uygulama sonuçlarımızı sunmak



# KÖK HÜCRE NEDİR?

## **Kök Hücre:**

- \* Hücrenin özelleşmemiş en temel ve saf halidir.
- \* Vücuttaki pek çok hücre tipine differensiye olabilir.
- \* Hasarlı hücre ve dokuları onarabilir.




# KÖK HÜCRE TEDAVİSİNİN MEKANİZMASI

- \* (1) Hücre Replasmanı: Sağlıklı kök hücreler dejenere hücrelerin yerini alabilir (Differensiasyon).
- \* (2) Nutrisyonel Destek: Sağlıklı kök hücreler salgıladıkları faktörlerle etraftaki hücrelerin yaşamlarını desteklerler.  
( bFGF, VEGF, M-CSF, GM-CSF, PlGF, TGF- $\beta$ , HGF, IGF-1, IL, angiogenin, Nöral GF'ler)
- \* (3) Yeni bağlantılar oluştururlar.



# EÜTF VE GENKÖK

*everything  
about life*





## FAZ II ÇALIŞMAMIZ

- \* Çalışma için kurumun etik kurulundan (No:2017/480 ) ayrıca T.C Sağlık Bakanlığı bünyesinde bulunan Organ Doku ve Diyaliz Hizmetleri Daire Başkanlığı'ndan (No: 56733164/203) onay alınmıştır.
- \* 20 olgu opere edildi. (4 YBMD, 3 Stargardt olgusu)



# HASTALAR VE YÖNTEM

- \* Görme düzeyi 0.05 düzeyinden daha düşük
- \* Olguların tek gözü (daha az gören gözü) çalışmaya alınmış
- \* Rutin oftalmolojik testler, renkli fundus fotoğrafı , FFA, OKT, FOF, mfERG
- \* Suprakoroidal olarak tek göze 0.2 ml 'de tek doz 3.pasajda,  $2 \times 10^6$  adipoz doku kaynaklı MKH uygulaması yapılmıştır.
- \* Postoperatif dönemde 1 ay süreyle topikal antibiyotik ve steroidli damla kullanılmıştır.



# SONUÇLAR

- \* Tüm olgular 6 aylık takiplerini tamamlamıştır.
- \* Hiçbir olguda sistemik komplikasyon olmadı.
- \* Hiçbir olguda okuler komplikasyon yok.
- \* Postop konjonktival hiperemi dışında olumsuz bulgu yok
- \* Reaksiyon yok



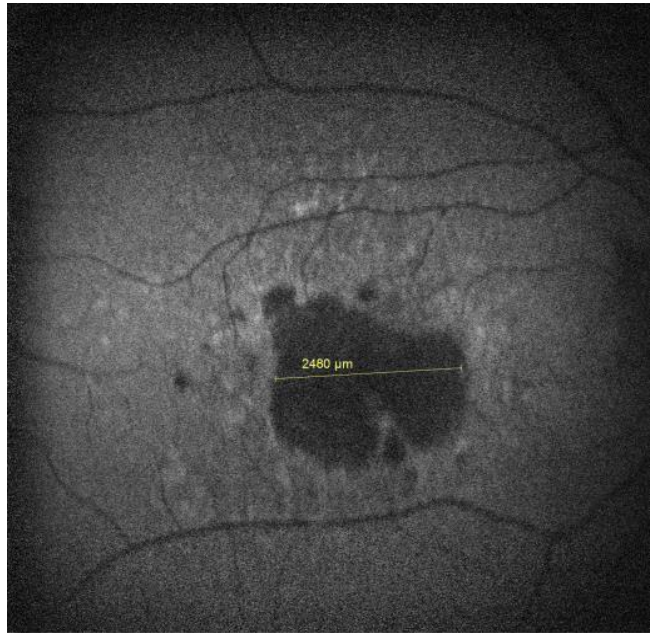- \* Takiplerde 7 olgunun hepsinde retina fonksiyonlarını gösteren mfERG ve PGA testlerinde iyileşme saptanmıştır.
- \* Takiplerde santral retina kalınlığında belirgin bir değişiklik olmaz iken santral koroid kalınlığı ortalama 225 mikrondan 265 mikrona yükselmiştir.
- \* Bu durum koroid kanlanmasının artışına yol açar ve retinanın daha iyi beslenmesini sağlar.



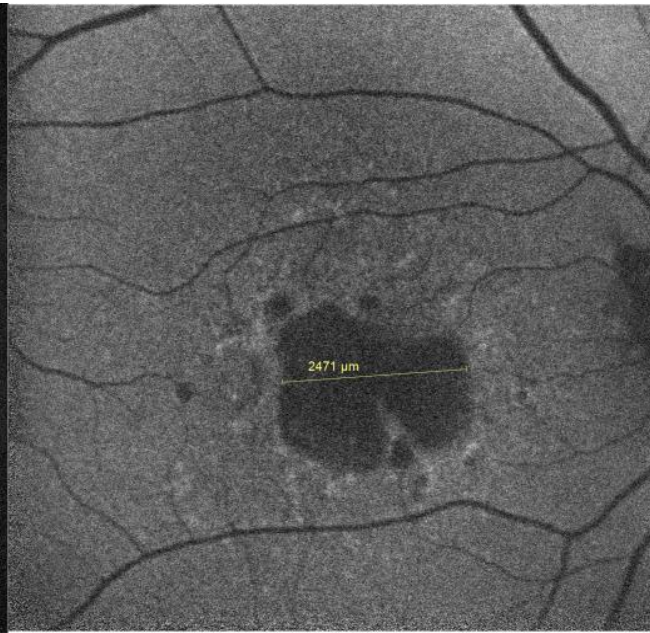
Olgu No.	Yaş/Cinsiyet	Hastalık/Göz	Başlangıç EİDGK (logMAR)	6. ayda EİDGK (logMAR)
1	19/F	STMD/OS	+1.3	+1.0
2	20/M	STMD/OD	+2.0	+1.5
3	31/F	STMD/OS	+1.5	+0.8
4	75/M	YBMD/OS	+1.8	+1.3
5	70/F	YBMD/OS	+2.0	+2.0
6	60/M	YBMD/OD	+1.8	+1.0
7	59/M	YBMD/OD	+2.0	+1.3



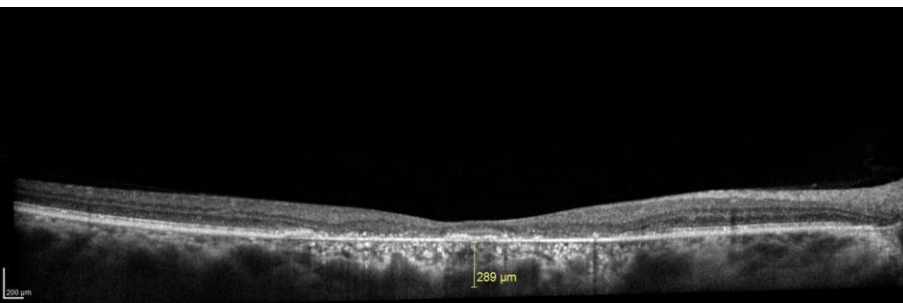
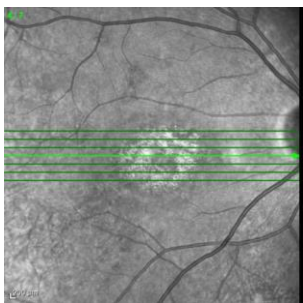
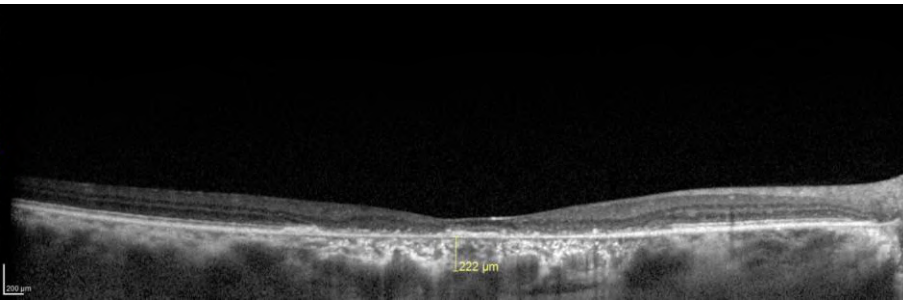
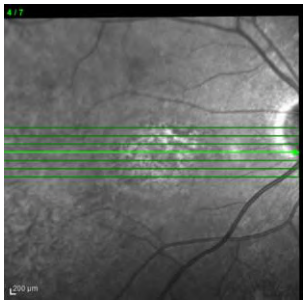
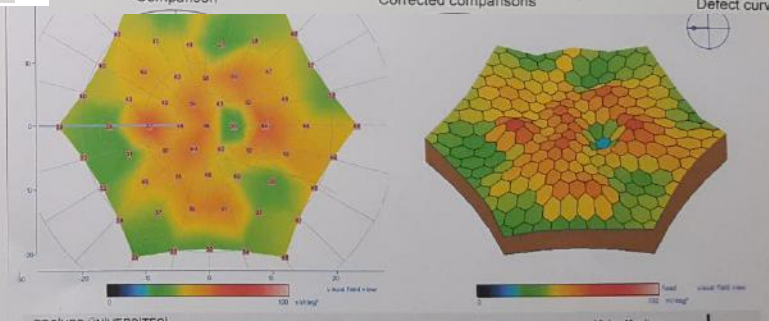
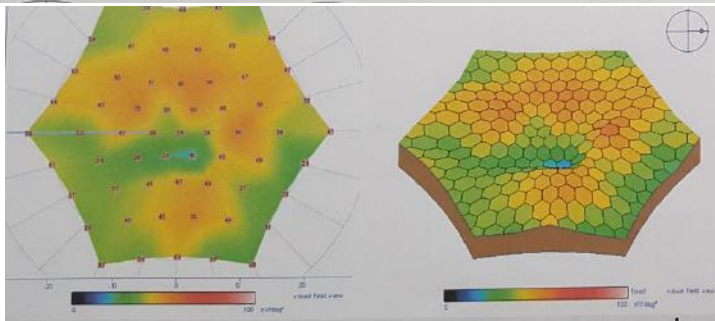
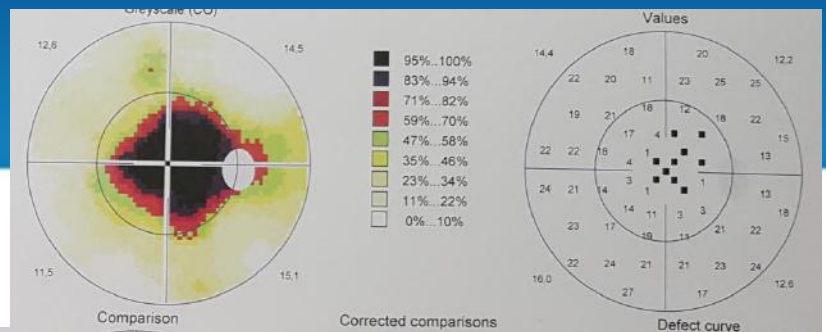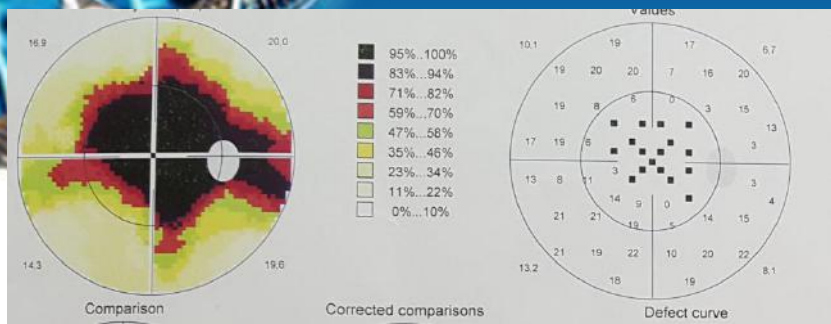
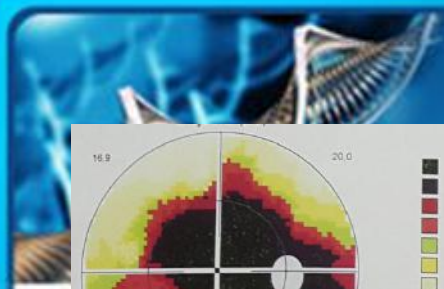
Olgu No.		Tedavi öncesi	1 ay	6 month
1	SMK	85	90	95
	SKK	403	428	435
	LB	2560	2530	2410
2	SMK	85	100	109
	SKK	218	227	263
	LB	2102	2017	1890
3	SMK	128	141	157
	SKK	232	248	278
	LB	2383	2331	2304
4	SMK	187	192	196
	SKK	90	126	130
	LB	3716	3663	3612
5	SMK	52	67	69
	SKK	73	96	108
	LB	5789	5718	5702
6	SMK	114	123	157
	SKK	398	431	466
	LB	2839	2830	2789
7	SMK	52	43	66
	SKK	156	158	171
	LB	2480	2479	2471

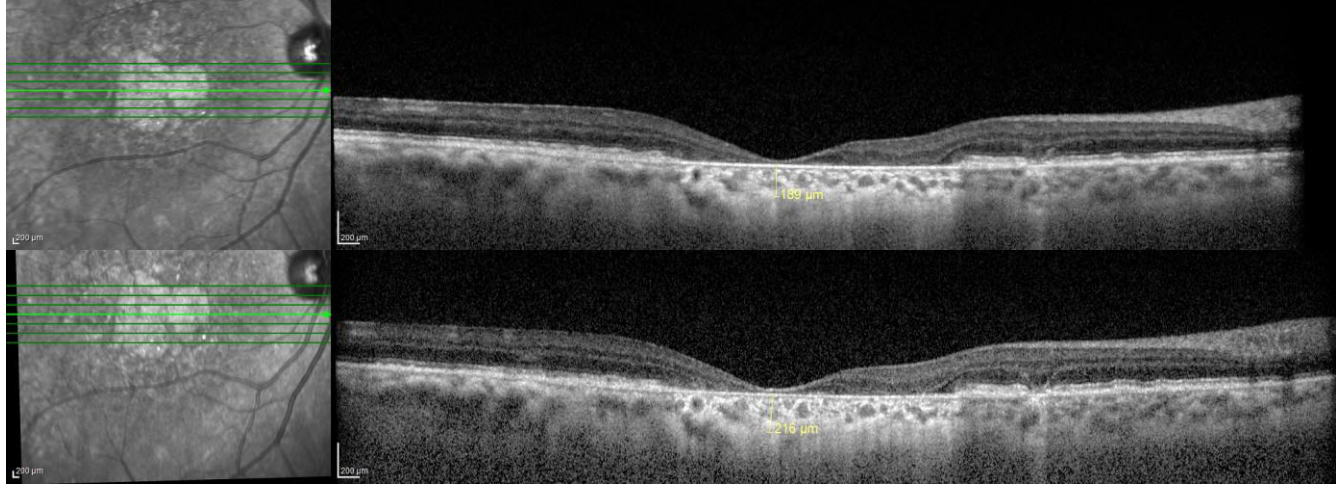
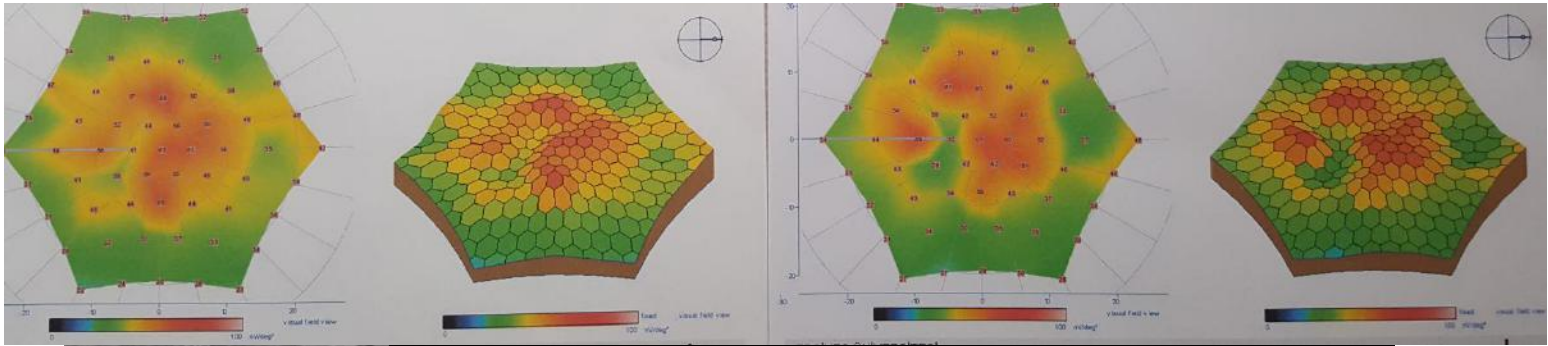
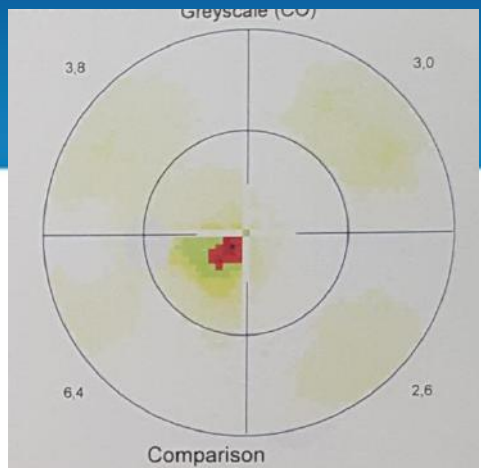
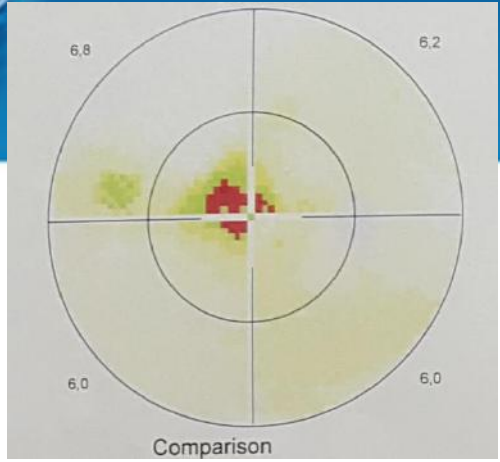



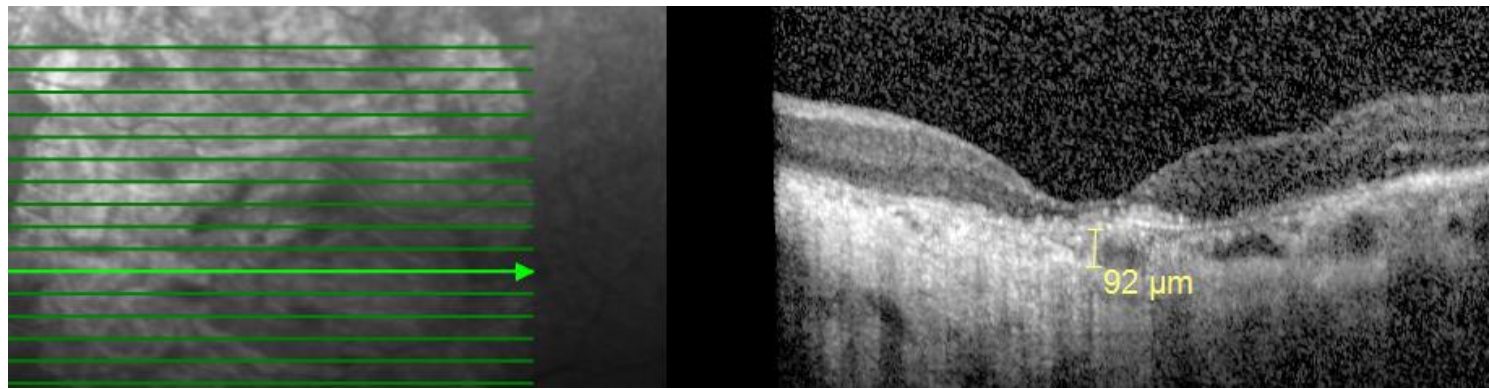
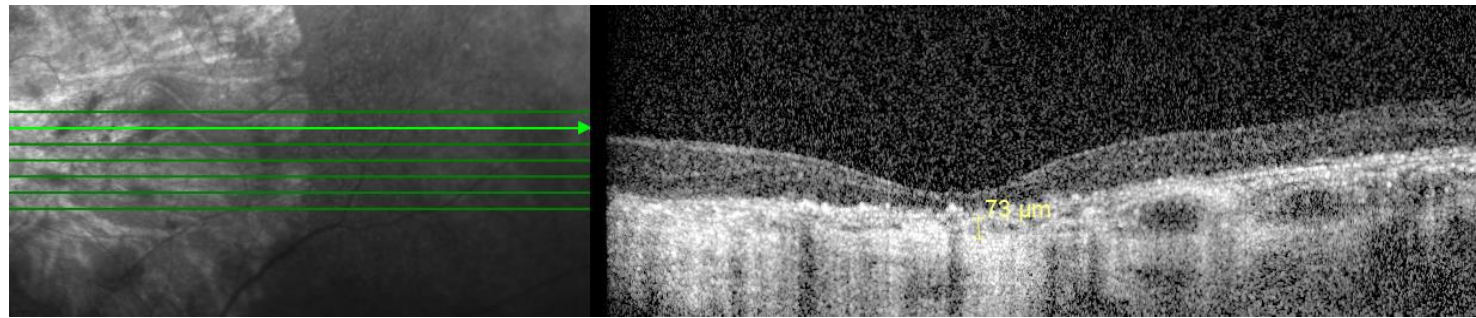
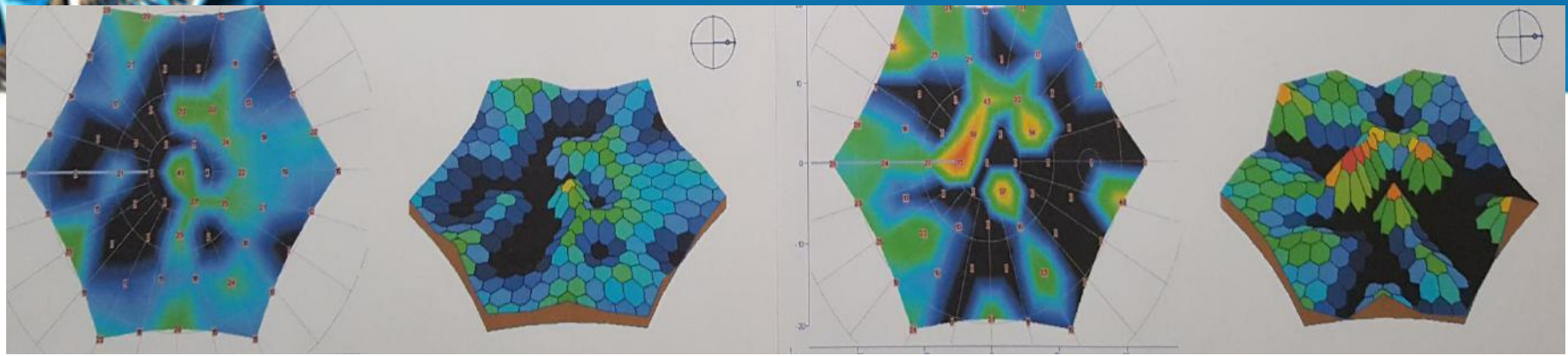

4A

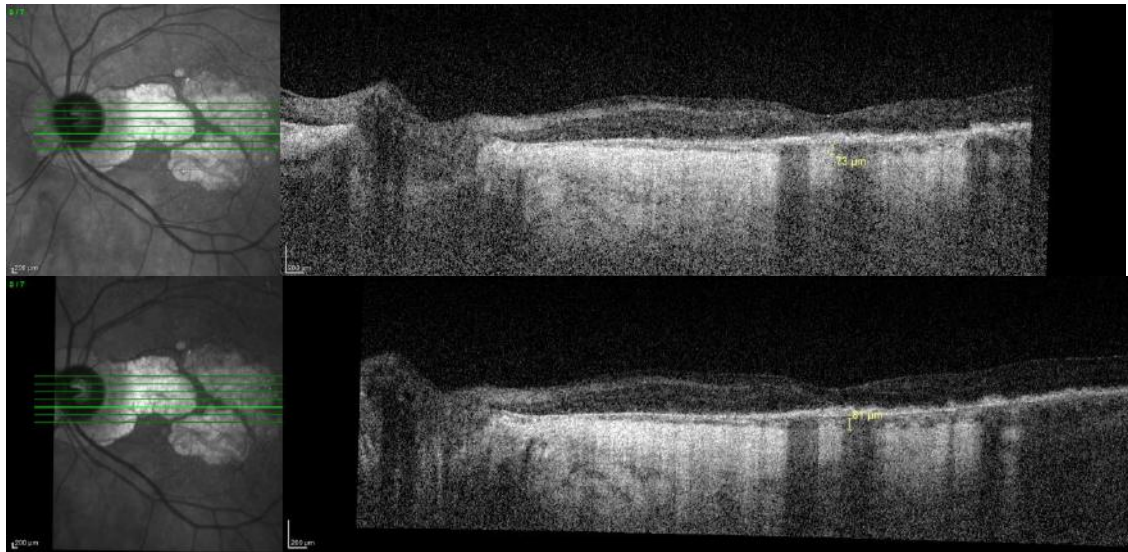
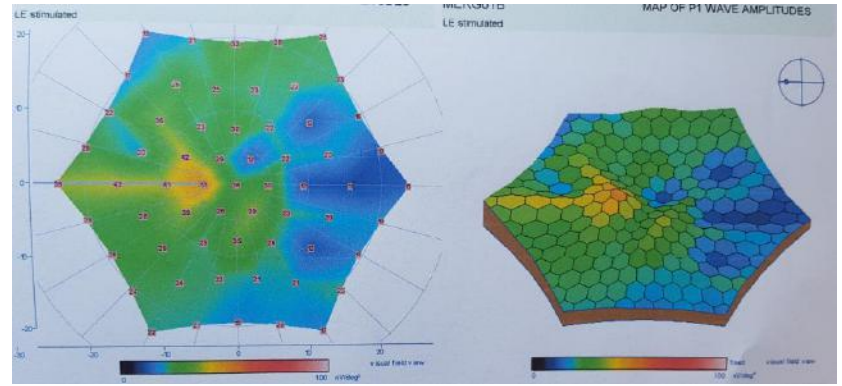
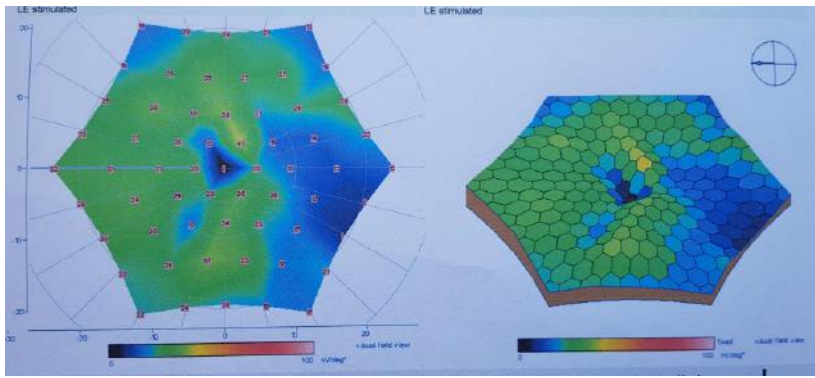
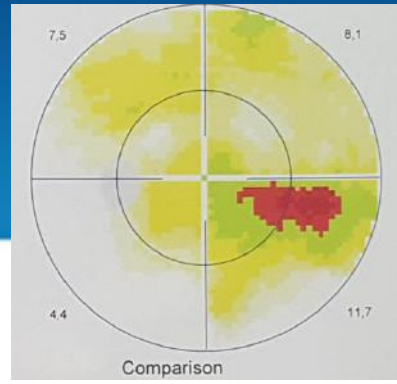
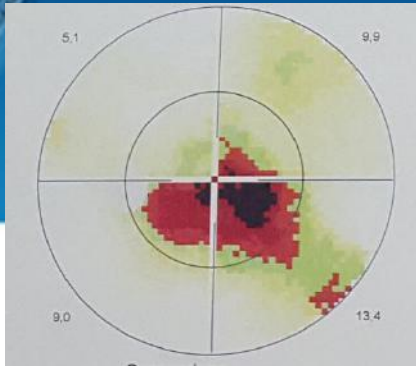


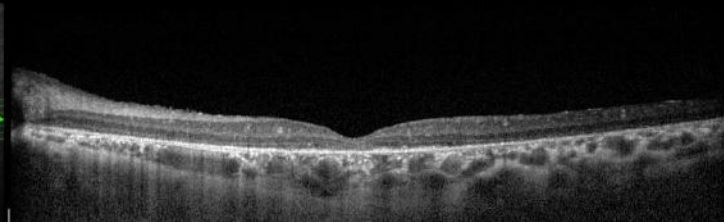
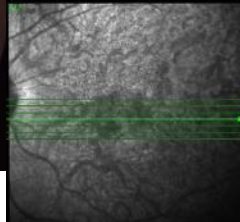
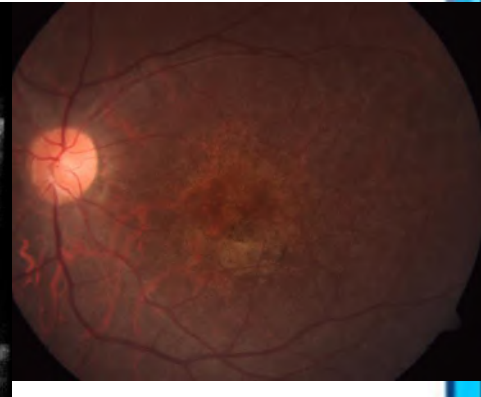
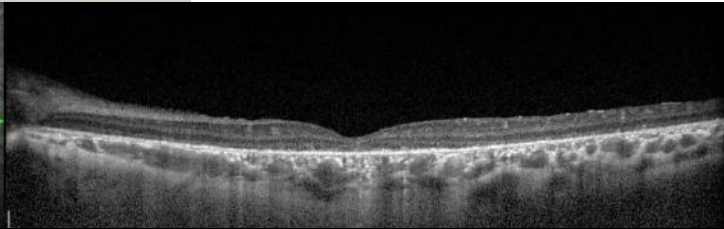
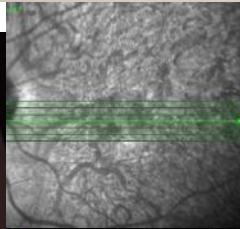
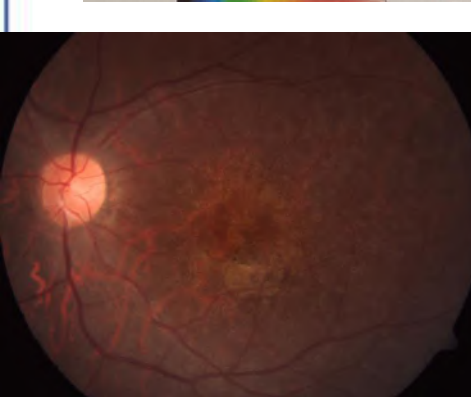
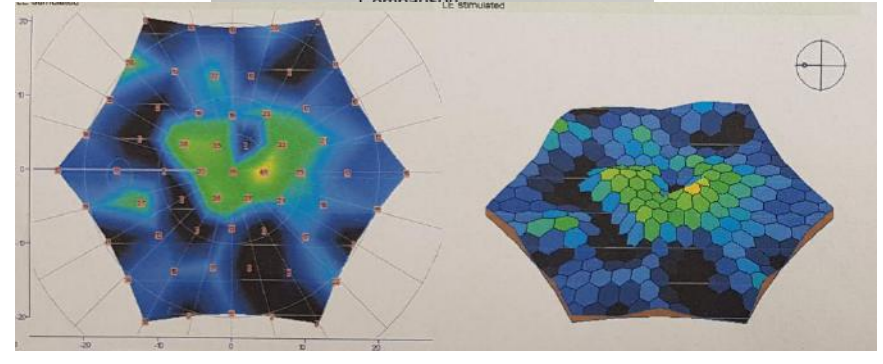
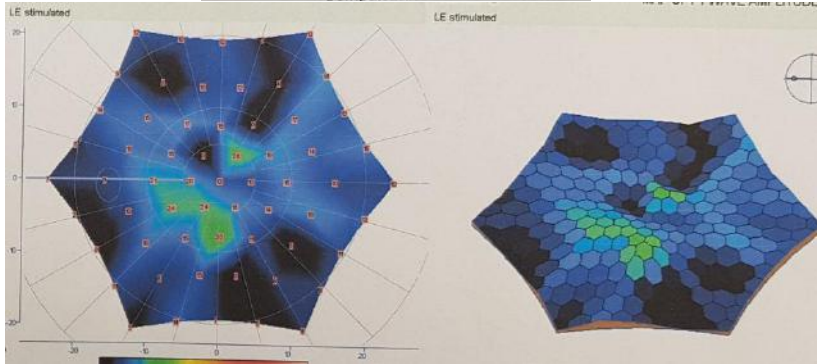
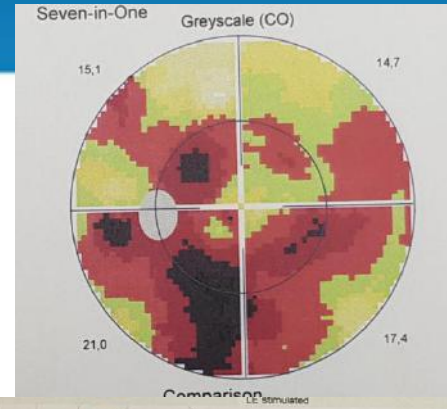
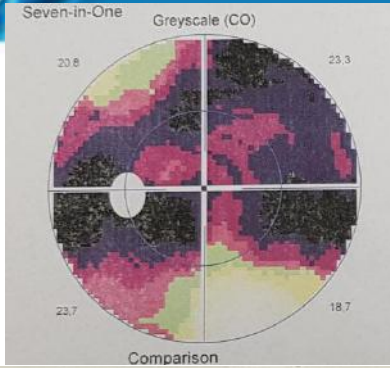
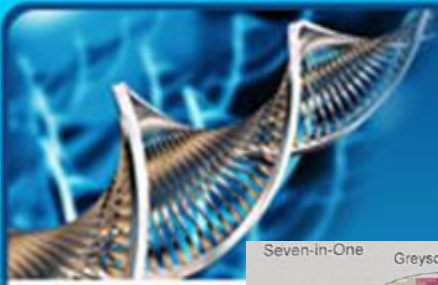
4B

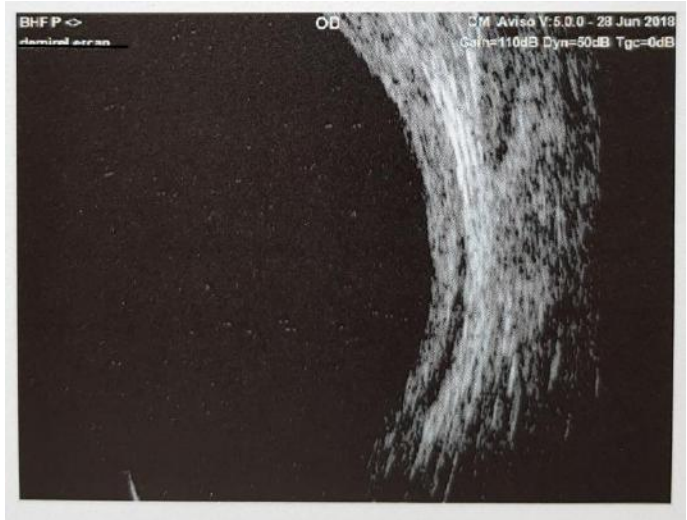
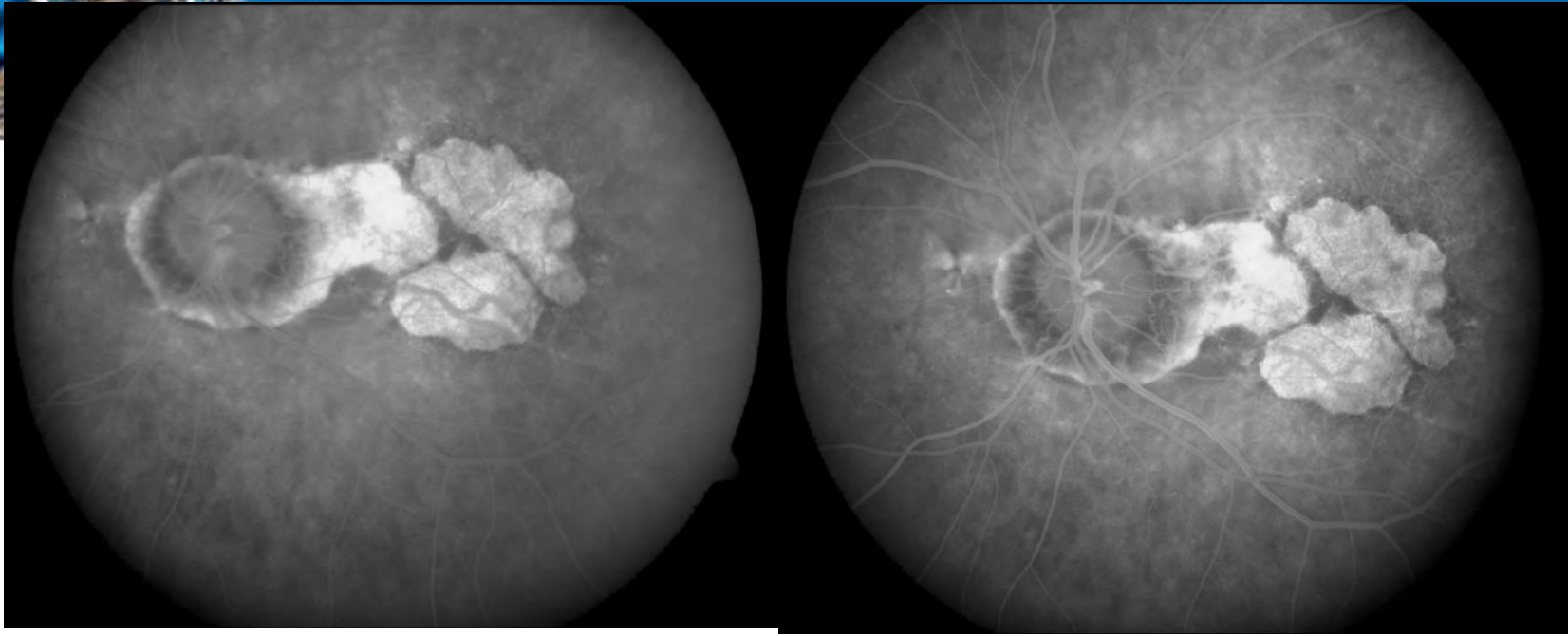
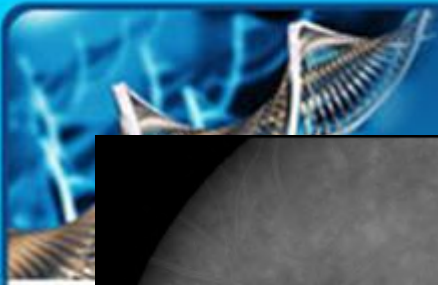















# MAKULA HASTALIKLARINDA KLİNİK ÇALIŞMALAR



## Cell surgery and growth factors in dry age-related macular degeneration: visual prognosis and morphological study

Paolo Giuseppe Limoli<sup>1</sup>, Celeste Limoli<sup>1</sup>, Enzo Maria Vingolo<sup>2</sup>, Sergio Zaccaria Scalinci<sup>3</sup> and Marcella Nebbioso<sup>4</sup>

J Vis Exp. 2018 Feb 12;(132). doi: 10.3791/56469.

### Regenerative Therapy by Suprachoroidal Cell Autograft in Dry Age-related Macular Degeneration: Preliminary In Vivo Report.

Limoli PG<sup>1</sup>, Vingolo EM<sup>2</sup>, Limoli C<sup>1</sup>, Scalinci SZ<sup>3</sup>, Nebbioso M<sup>4</sup>.

## 25 OLGUNUN 36 GÖZÜ KURU TİP YBMD SUPRAKOROİDAL ADMKH

**Table 3: Patient compliance analysis (PCA) shows that, at 6 months post surgery, 19 of 36 eyes (52.78%) recorded better vision, 14 (38.89%) no change in functional situation, and 3 (8.33%) a worsening.**

PCA	Group A	Group B	Total
Number of eyes	14	22	36
Improved (%)	5 (35.71)	14 (63.64)	19 (52.78)
Unchanged (%)	7 (50)	7 (31.82)	14 (38.89)
Worse (%)	2 (14.29)	1 (4.55)	3 (8.33)

Among the 19 eyes of patients who noted an improvement at 6 months post surgery, 5 (26.3%) belong to group A and 14 (73.7%) to group B.

## Evaluating role of bone marrow-derived stem cells in dry age-related macular degeneration using multifocal electroretinogram and fundus autofluorescence imaging

*Atul Kumar<sup>1</sup>, Neha Midha<sup>1</sup>, Sujata Mohanty<sup>2</sup>, Annu Chohan<sup>1</sup>, Tulika Seth<sup>3</sup>, Varun Gogia<sup>1</sup>, Shikha Gupta<sup>1</sup>*

30 hasta, santral GA olan olgular, GK 0.1 den düşük olanlar

Kötü olan göze otolog Ki- MKH

6 aylık takip, Mf ERG de iyileşme

GA boyutunda küçülme (Diğer gözde büyüme)

GK'de fark yok (Diğer gözde azalma)

# Intravitreal use of bone marrow mononuclear fraction containing CD34<sup>+</sup> stem cells in patients with atrophic age-related macular degeneration

This article was published in the following Dove Press journal:  
Clinical Ophthalmology  
19 May 2017  
[Number of times this article has been viewed](#)

10 ATROFİK YBMD, GK 20/100 DEN DÜŞÜK OLGULAR

OTOLOG Kİ-MKH, İNTRAVİTREAL

GK ' DE ANLAMLI ARTIŞ (20/320 DEN 20/200'E YÜKSELMİŞ)

PERİMETRİDE İYİLEŞME

ATROFİK ALANLARDA KÜÇÜLME