

# Dejeneratif retina hastalığı olan pediatrik olgularda suprakoroidal mezenkimal kök hücre uygulaması: 6 aylık takip sonuçlarımız

AYŞE ÖNER, FEBO, NESLİHAN SİNİM KAHRAMAN, FICO, FEBO

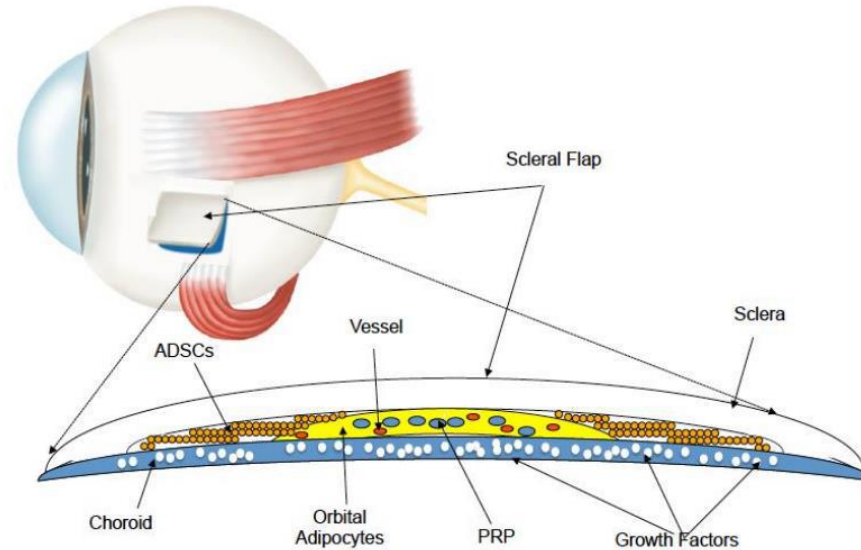
ACIBADEM ÜNİVERSİTESİ ATAKENT HASTANESİ-İSTANBUL

# AMAÇ

- ▶ Dejeneratif retina hastalığı olan (Retinitis Pigmentosa- RP ve Stargardt Makula Distrofisi- SMD)
- ▶ 11 pediatrik olguda
- ▶ Suprakoroidal mezenkimal kök hücre (MKH) uygulamasının
- ▶ Güvenilirliğini ve etkinliğini arařtırmak amaçlanmıřtır.
- ▶ Çalışma için Etik Onay ve Sağlık Bakanlıęı Organ Doku ve Kök Hücre Nakli Kurulu'ndan onay alınmıřtır.

# METOD

- ▶ 11 olgunun
- ▶ 11 gözüne (Çoğunlukla daha az gören gözüne) Limoli Retinal Restorasyon Tekniđi ile suprakoroidal olarak
- ▶ 5 milyon MKH implante edildi.



# KÖK HÜCRE TEDAVİSİNİN MEKANİZMASI

**Nutrisyonel Destek:** Sağlıklı kök hücreler salgıladıkları faktörlerle etraftaki hücrelerin yaşamlarını desteklerler (Parakrin, Trofik etki)

- ▶ Proangiogenik faktörler: Angiogenin, PLGF
- ▶ Angiogenik kemokinler: CXCL1, CXCL2, CXCL5, CXCL6 ve CXCL8
- ▶ Angiogenik growth faktörler: HGF, bFGF, VEGF-D, PDGF-AA, TGF- $\beta$ 2, G-CSF, TGF- $\beta$ 1
- ▶ Nörotrofik faktörler: bFGF, nerve growth factor (NGF), neurotrophin 3 (NT3), neurotrophin 4 (NT4), glial-derived neurotrophic factor (GDNF)
- ▶ Hematopoietik growth faktörler: G-CSF, GM-CSF, LIF, IL-1 $\alpha$ , IL-6, IL-8, and IL-11.

# METOD

- ▶ Olgular postoperatif 1. gün sonrasında 1., 3. ve 6. aylarda değerlendirildi.
- ▶ Her kontrolde görme keskinliği, ön ve arka segment muayenesi, optik kohorens tomografi (OKT) yapıldı.
- ▶ İşlem öncesi ve 6. ay kontrolünde ise multifokal elektroretinografi (mf ERG) testi ve görme alanı tekrarlandı.

# BULGULAR

- ▶ Olguların 9'unda RP, 2'sinde SMD
- ▶ Yaş aralığı 5 ile 18 arasında değişmekteydi.
- ▶ Preoperatif görme keskinliği 1 mps ile 0.60 Snellen sırası arasında değişmekteydi.
- ▶ Olguların hepsi minimum 6 aylık takip süresini tamamladı.
- ▶ Hiçbir olguda sistemik ya da oküler bir yan etki gelişmedi.

# BULGULAR

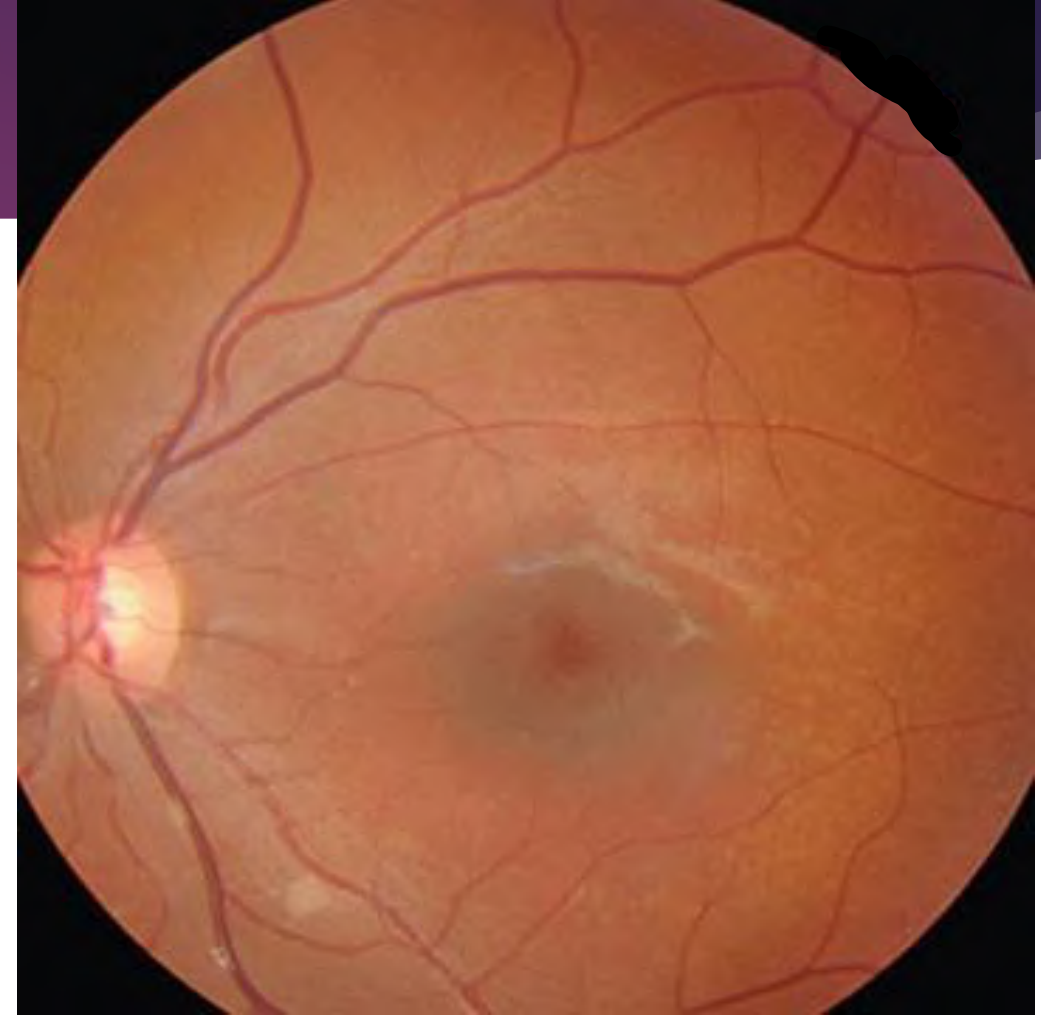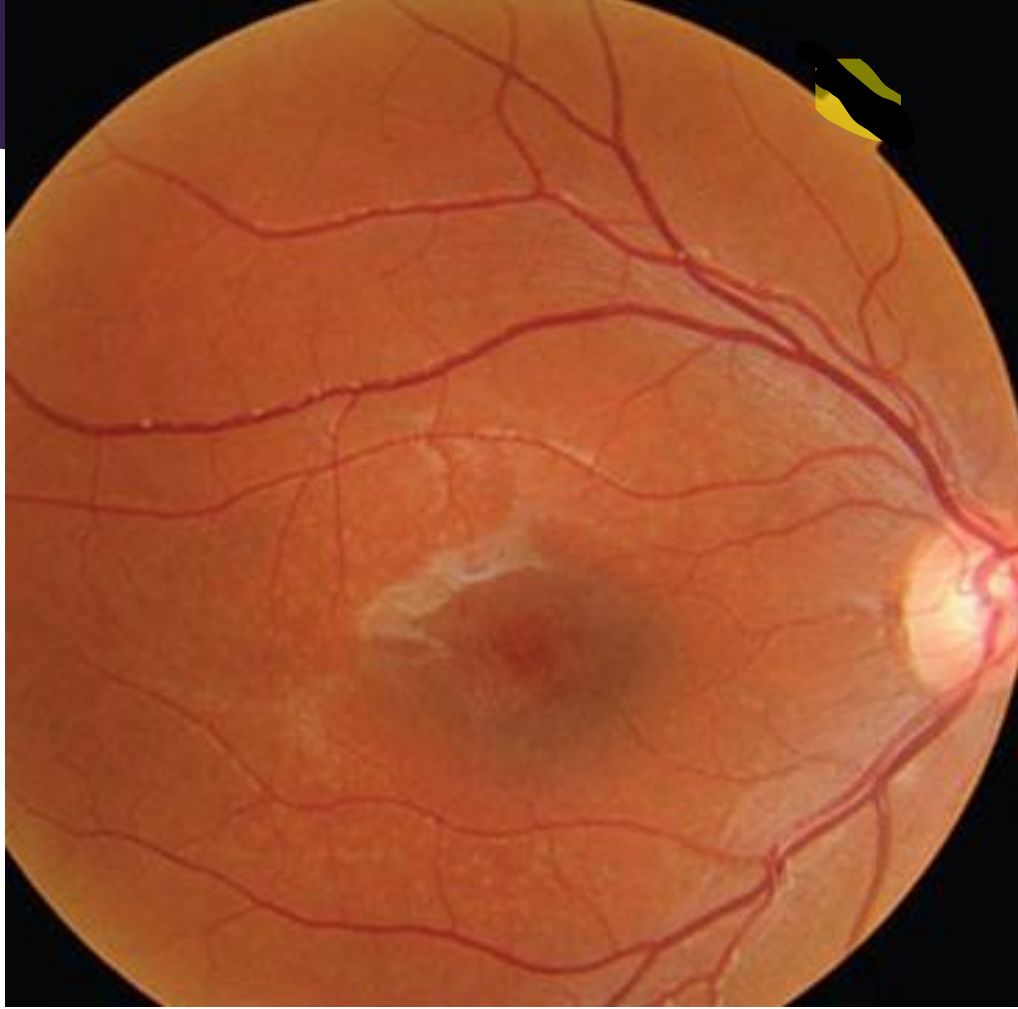
- ▶ Görme keskinliđi 10 gözde artarken, 1 gözde stabil seyretti.
- ▶ Görme keskinliđi artan gözlerde aynı zamanda görme alanı ve mfERG bulgularında da iyileşme saptandı.
- ▶ Takiplerde OKT'de herhangi bir patolojiye rastlanmadı.
- ▶ Olguların tedavi edilmeyen diđer gözleri deđerlendirildiđinde takip süresi sırasında görme keskinliđi 6 gözde azalırken 5 gözde stabil seyretti.

Olgu	Tanı	Yaş	Preop GK	Postop GK
N.G	RP	14	1mps	2 mps
H.T	RP	5	1mps	0.05
M.Y	RP	10	0.15	0.2
S.Y	RP	17	0.6	0.8
E.B	RP	11	0.10	0.15
F.B	RP	17	<b>0.10</b>	<b>0.10</b>
A.İ.G	SMD	10	0.05	0.20
E.E	RP	13	0.15	0.20
Ç.U	SMD	12	0.10	0.20
F.O	RP	17	2 mps	0.05
E.A	RP	17	0.05	0.15

		<b>Preop</b>	<b>Postop. 1.ay</b>	<b>Postop. 6.ay</b>	<b>P value*</b>
PGA (dB)	Ort±SS	-28.12±3.18	-26.17±4.21	-24.19±3.23	<0.05

## Amplitude of P1 wave (nanovolt) (n=11)

HALKALAR		PREOP	POSTOP 6.AY
<2°	Median (IQR)	265.0 (196.5-475.5)	293.0 (209.0-484.5)*
	Mean±SD	340.7±197.4	361.8±217.6*
2-5°	Median (IQR)	139.0 (108.5-244.0)	156.0 (112.0-239.5)*
	Mean±SD	196.7±138.7	209.3±151.1*
5-10°	Median (IQR)	83.0 (67.0-116.0)	76.0 (63.5-114.5)
	Mean±SD	115.3±84.8	111.8±98.0
10-15°	Median (IQR)	63.0 (50.0-78.5)	54.0 (45.0-74.0)
	Mean±SD	77.9±51.0	73.1±49.7
>15°	Median (IQR)	42.0 (33.0-64.0)	35.0 (29.0-50.5)
	Mean±SD	52.9±38.9	46.6±31.9

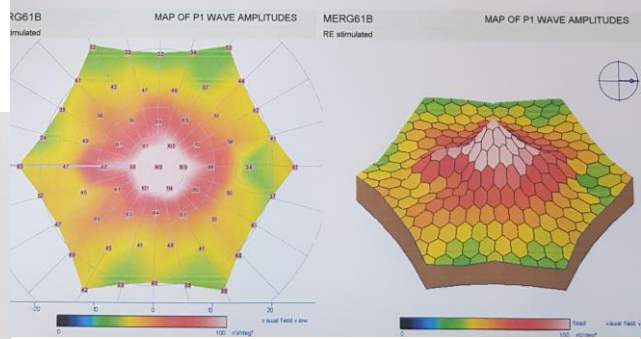
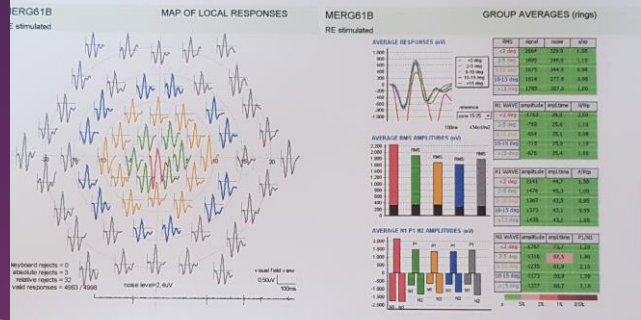


OLGU 1, SMD, 11 yaş kız çocuđu

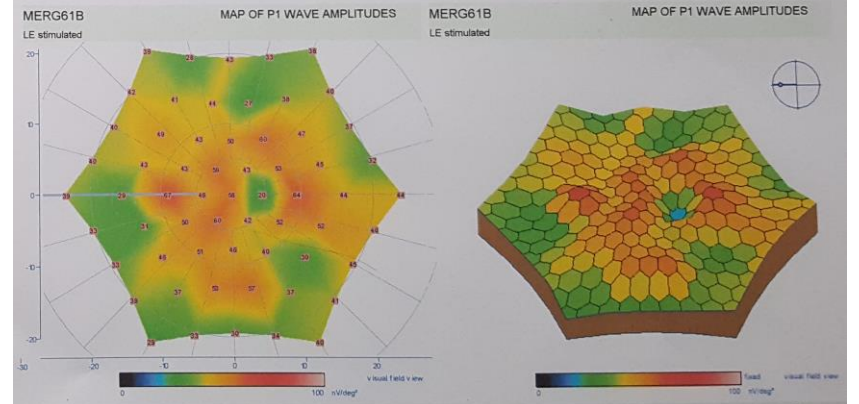
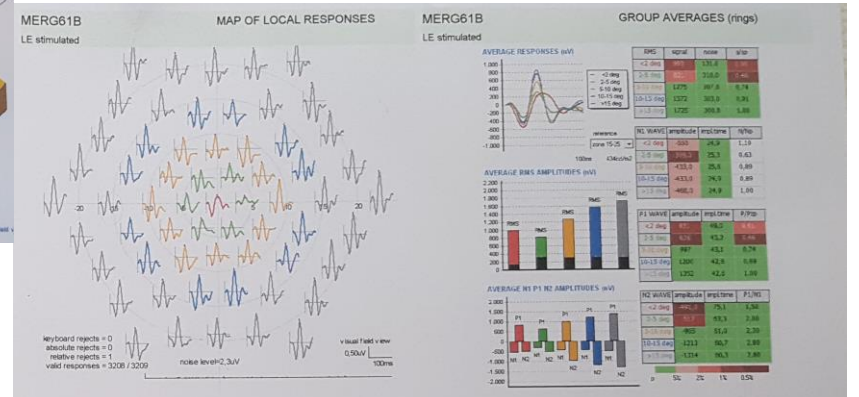
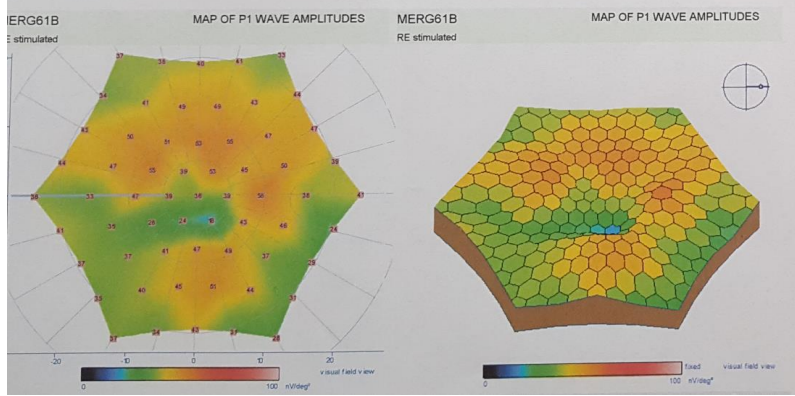
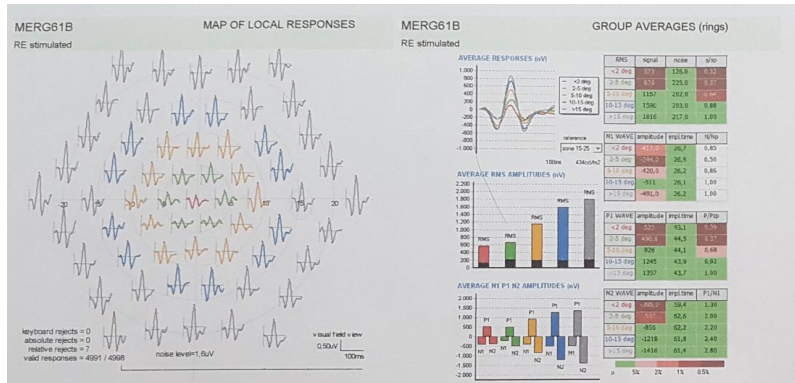


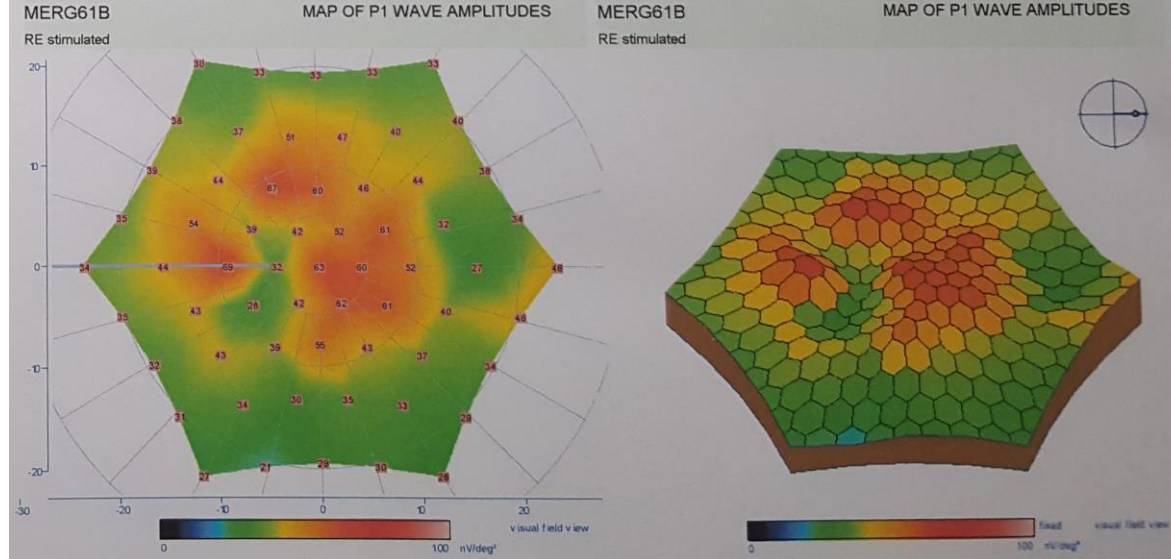
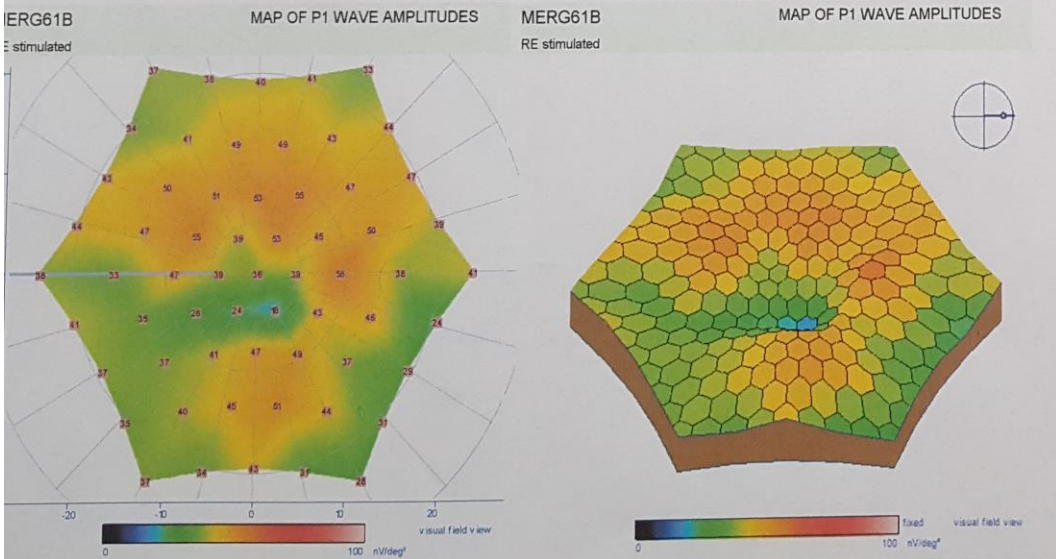
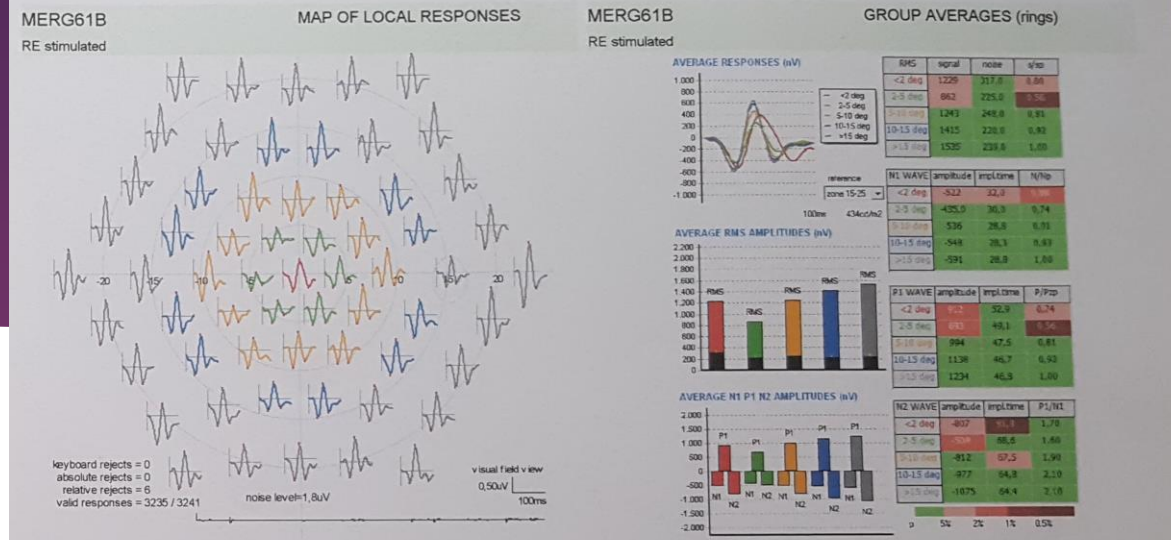
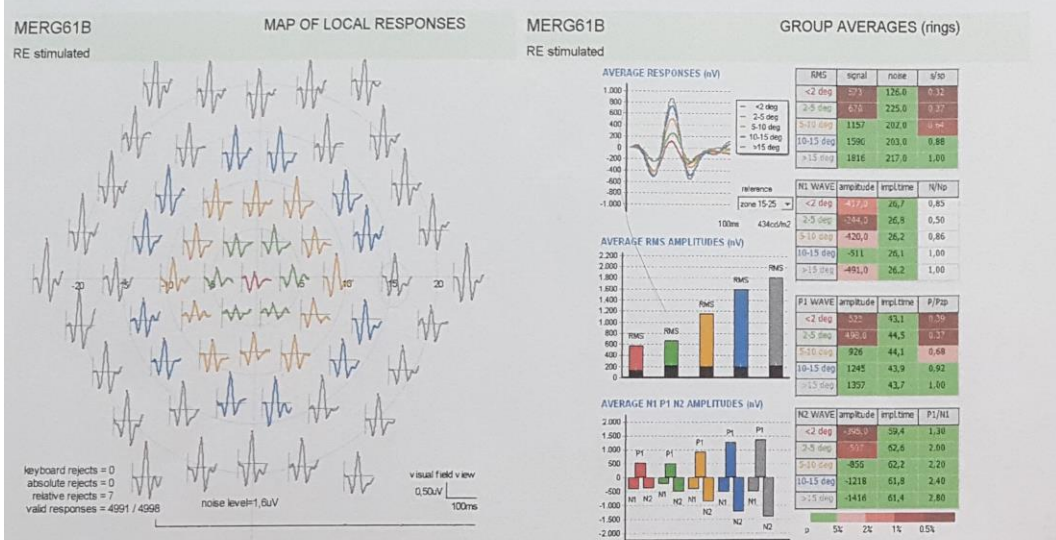
# Mf ERG

SAĞ



SOL

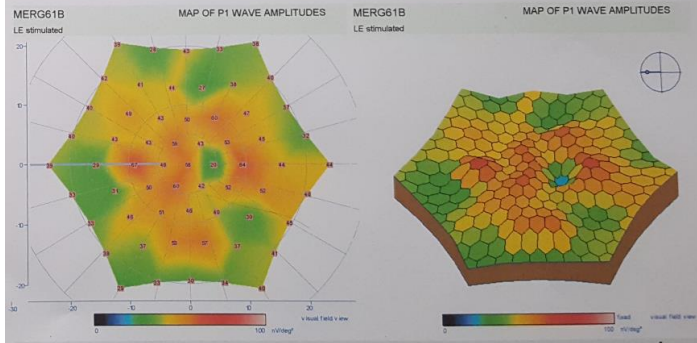
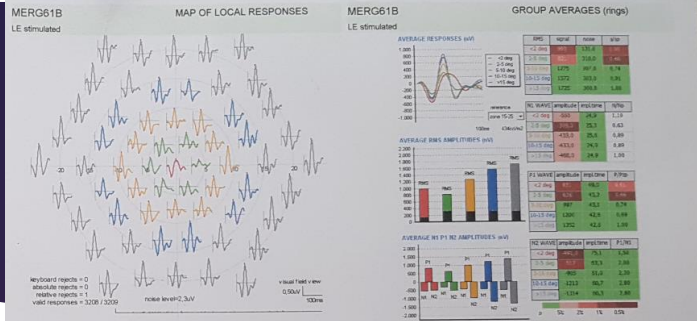




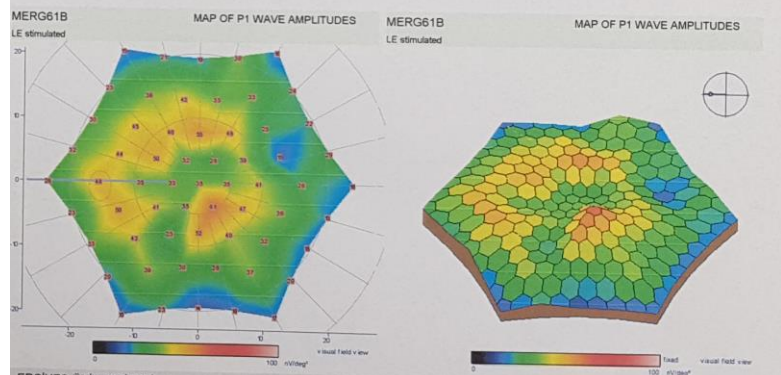
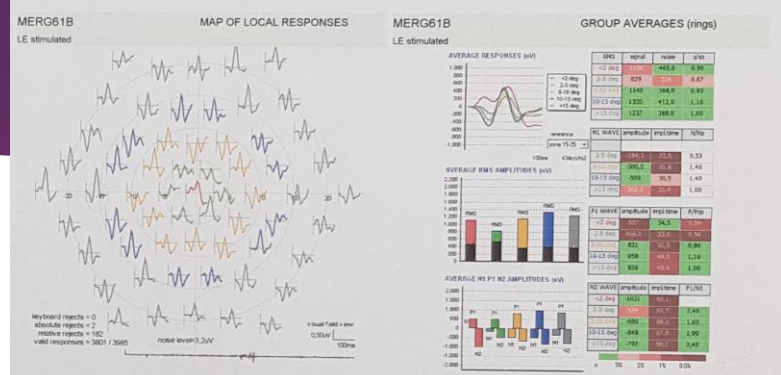GK: 0.05

SAĞ GÖZ

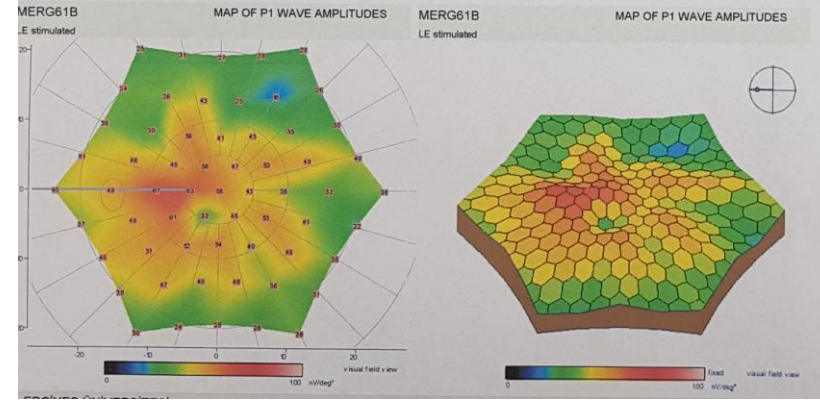
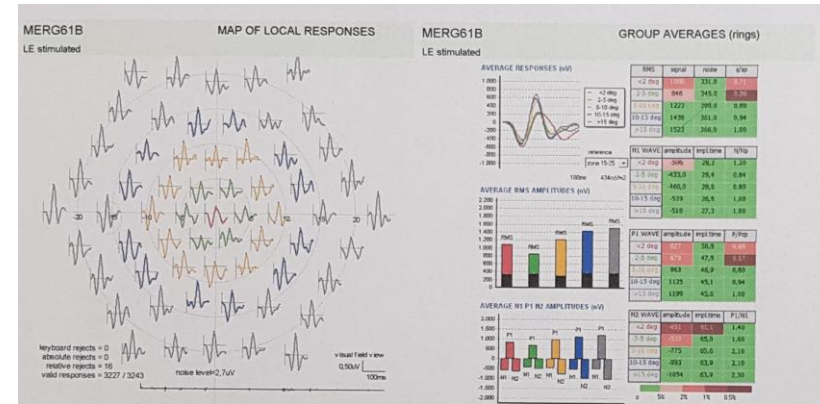
GK: 0.20



GK: 0.7







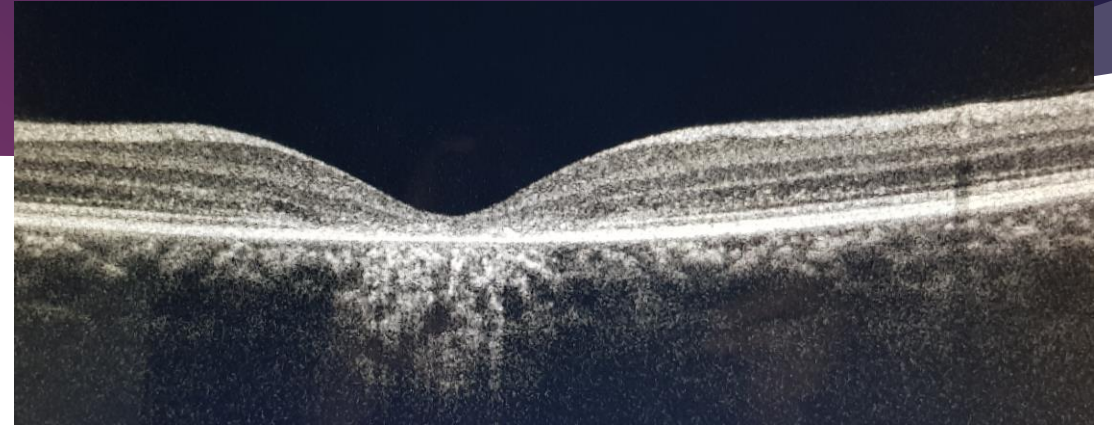
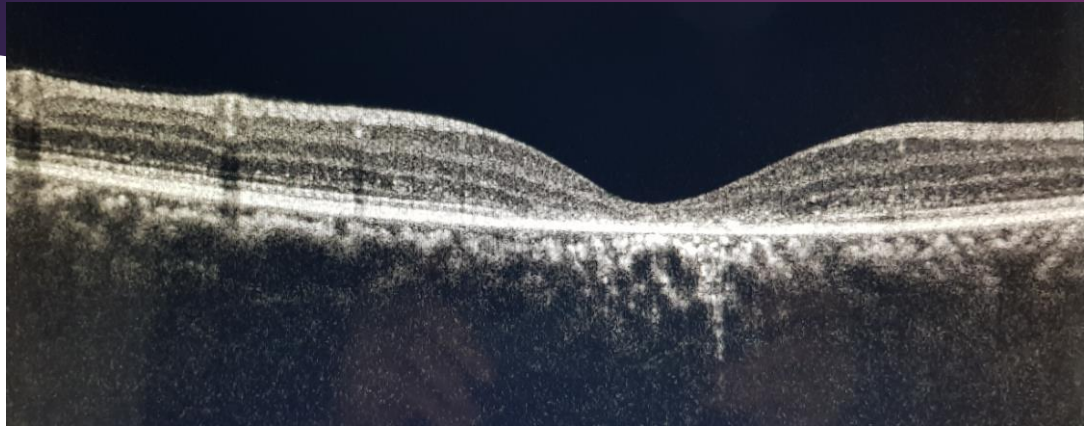
GK: 0.2



GK: 0.4

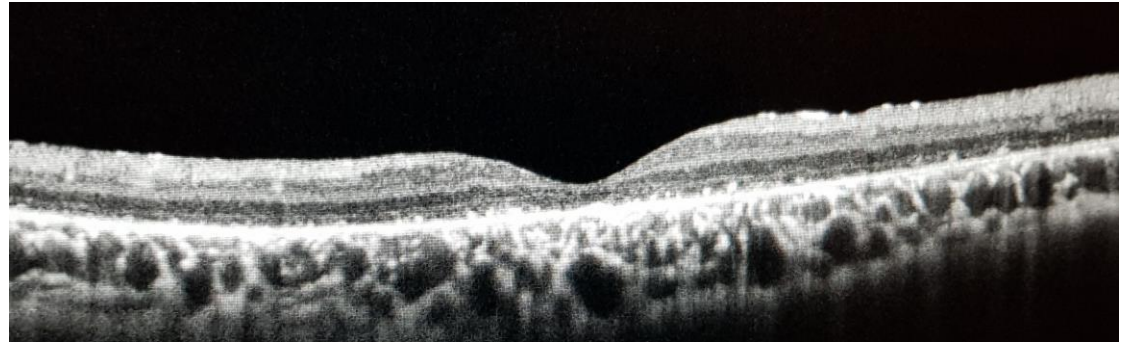
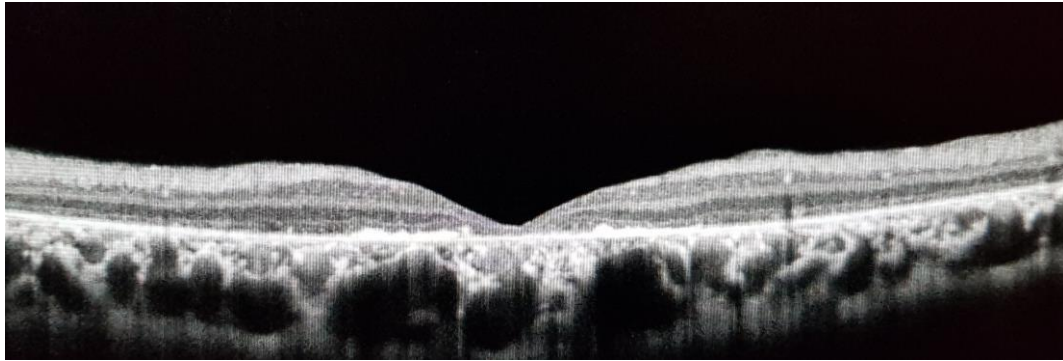


SOL GÖZ




# OCT VEGA



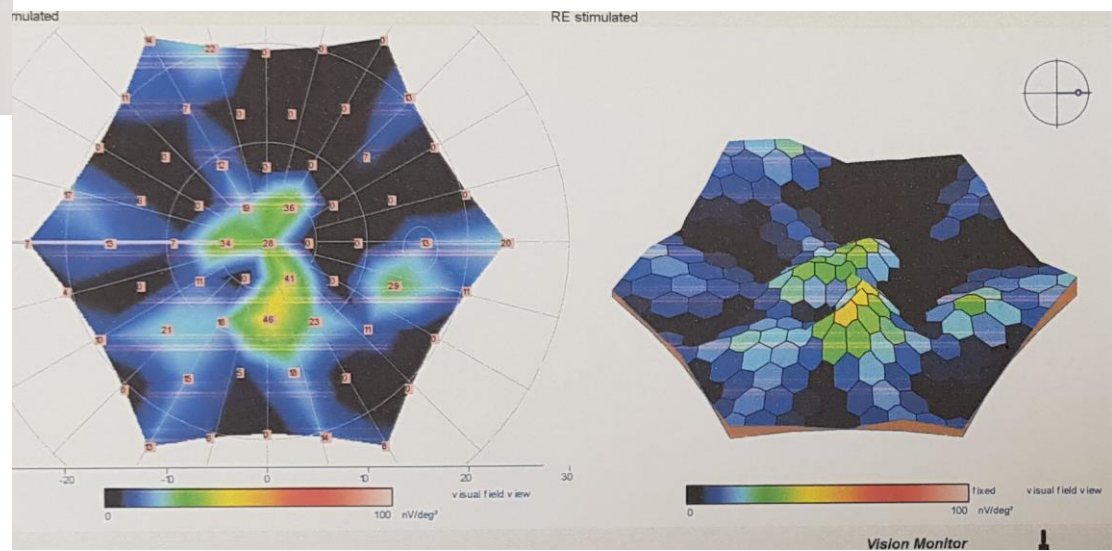
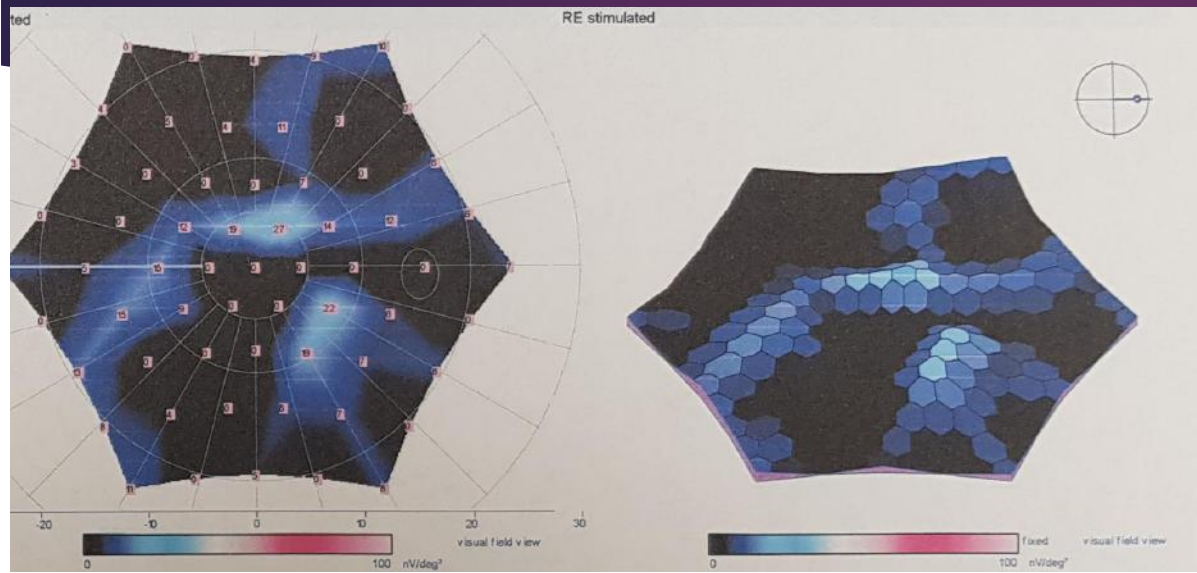
# OLGU 2: RP

- ▶ 12 y, erkek
- ▶ Sol göz 3 yıldır sadece ışık görüyor
- ▶ Sağ gözde GK: 0.6





MD: -28.39/ -27.96/ -26.56



**Suprachoroidal Adipose Tissue-Derived Mesenchymal Stem Cell Implantation in Patients with Dry-Type Age-Related Macular Degeneration and Stargardt's Macular Dystrophy: 6-Month Follow-Up Results of a Phase 2 Study**

Ayşe Oner,<sup>1</sup> Zeynep Burcin Gonen,<sup>2,3</sup> Duygu Gülmez Sevim,<sup>4</sup>  
Neslihan Sinim Kahraman,<sup>4</sup> and Metin Unlu, MD<sup>5</sup>

eISSN 2005-5447

International Journal of Stem Cells Published online October 31, 2020

<https://doi.org/10.15283/ijsc20025>

**ORIGINAL ARTICLE**

**First Year Results of Suprachoroidal Adipose Tissue Derived Mesenchymal Stem Cell Implantation in Degenerative Macular Diseases**

Neslihan Sinim Kahraman<sup>1</sup>, Zeynep Burcin Gonen<sup>2</sup>, Duygu Gulmez Sevim<sup>3</sup>, Ayşe Oner<sup>1</sup>

<sup>1</sup>Ophthalmology Department, Kayseri Acibadem Hospital, Kayseri, Turkey

<sup>2</sup>Genome and Stem Cell Center, Kayseri, Turkey

<sup>3</sup>Ophthalmology Department, Erciyes University, Kayseri, Turkey

Int J Ophthalmol, Vol. 13, No. 9, Sep.18, 2020 [www.ijo.cn](http://www.ijo.cn)

Tel: 8629-82245172 8629-82210956 Email: [ijopress@163.com](mailto:ijopress@163.com)

• Clinical Research •

**Umbilical cord derived mesenchymal stem cell implantation in retinitis pigmentosa: a 6-month follow-up results of a phase 3 trial**

*Neslihan Sinim Kahraman, Ayşe Oner*

# SONUÇLAR

- ▶ Dejeneratif retina hastalığı olan pediatrik olguların tedavisinde suprakoroidal MKH uygulaması güvenli ve etkili bir tedavi seçeneđi **olabilir**.
- ▶ Bu konuda gelecekte yapılacak daha çok olgu içeren çalıřmalara ihtiyaç vardır.