




RETİNAL KÖK HÜCRE NAKLİ SONRASI
ELEKTROFİZYOLOJİK BULGULAR

Prof.Dr. Ayşe Öner, FEBO
Acıbadem Sağlık Grubu
Kayseri Acıbadem Hastanesi
KAYSERİ

KÖK HÜCRE NEDİR?

Kök Hücre:

- * Hücrenin en temel ve en saf halidir.
- * Vücuttaki pek çok hücre tipine differensiye olabilir.
- * Hasarlı hücre ve dokuları onarabilir.





KÖK HÜCRELERİN ÖZELLİKLERİ

- Proliferasyon
- Self-renewal: Kendini yenileme
- Differensiasyon



KÖK HÜCRE TEDAVİSİNİN MEKANİZMASI

- * **(1) Hücre Replasmanı:** Sağlıklı kök hücreler dejenere hücrelerin yerini alabilir (Differentiasyon).
- * Bu süreçte internal ve eksternal faktörler rol alır.
- * **İnternal faktörler:** Hücrenin genleriyle ilişkilidir.
- * **Eksternal faktörler:** Hücrenin bulunduğu ortamdaki diğer hücreler ve moleküllerle (microenvironment) ilişkilidir.



KÖK HÜCRE TEDAVİSİNİN MEKANİZMASI

- * **(2) Nutrisyonel Destek:** Sağlıklı kök hücreler salgıladıkları faktörlerle etraftaki hücrelerin yaşamlarını desteklerler (Parakrin, Trofik etki)
- * Proangiogenik faktörler: Angiogenin, PLGF
- * Angiogenik kemokinler: CXCL1, CXCL, CXCL5, CXCL6 ve CXCL8
- * Angiogenik growth faktörler: HGF, bFGF, VEGF-D, PDGF-AA, TGF- β 2, G-CSF, TGF- β 2
- * Nörotrofik faktörler: bFGF, nerve growth factor (NGF), neurotrophin 3 (NT3), neurotrophin 4 (NT4), glial-derived neurotrophic factor (GDNF)
- * Hematopoietik growth faktörler: G-CSF, GM-CSF, LIF, IL-1 α , IL-6, IL-8, and IL-11.
- * **(3) İmmunomodulatör etki**



Gözde Kök Hücre Kullanımı

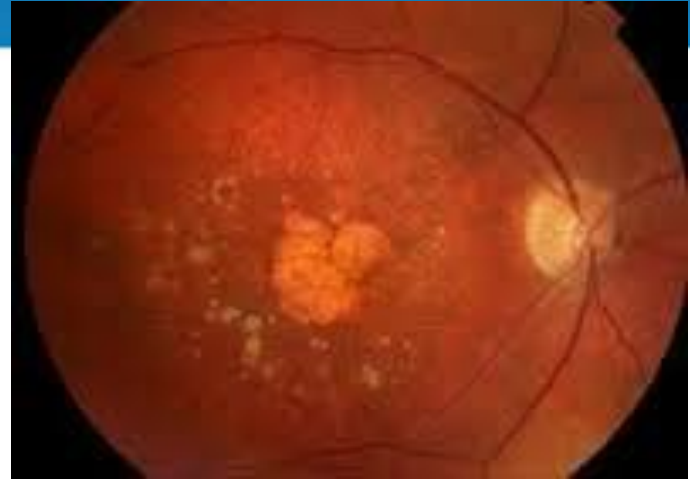
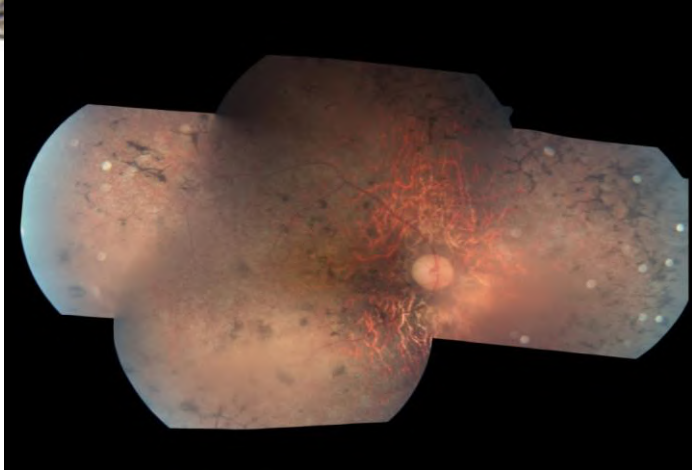
- * Çok küçük dozlar yeterli olur.
- * Cerrahi yaklaşım kolaydır.
- * Nakledilen hücre kolayca izlenir.
- * Gözün immün yapısı uygundur.
- * Diğer göz kontrol olarak kullanılabilir.
- * Ekstraoküler yayılım söz konusu değildir.



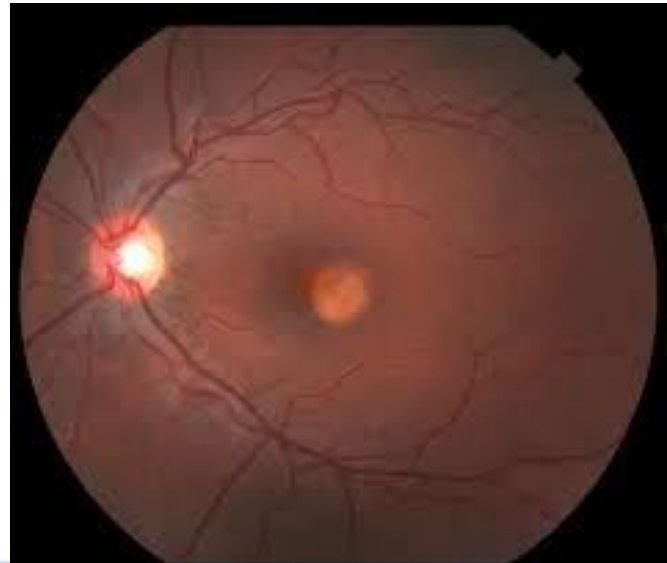
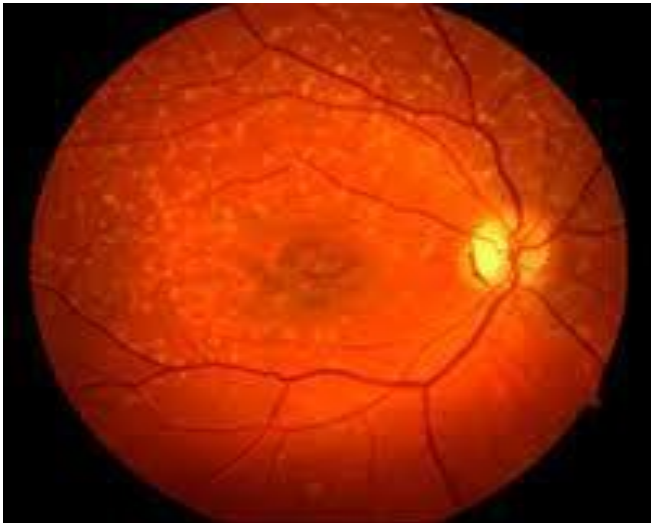Kök Hücre Uygulamalarında Cerrahi Yaklaşım

- * 1- İntravitreal
- * 2-PPV and Subretinal
- * 3- Suprakoroidal
- * 4-Retrubulber/Subtenon
- * 5-İntravenöz

HEDEFLENEN RETİNAL HASTALIKLAR



RP, Leber KA, YBMD, BEST, STARGARDTS'





Oner et al. *Stem Cell Research & Therapy* (2016) 7:178
DOI 10.1186/s13287-016-0432-y

Stem Cell Research & Therapy

RESEARCH


Open Access



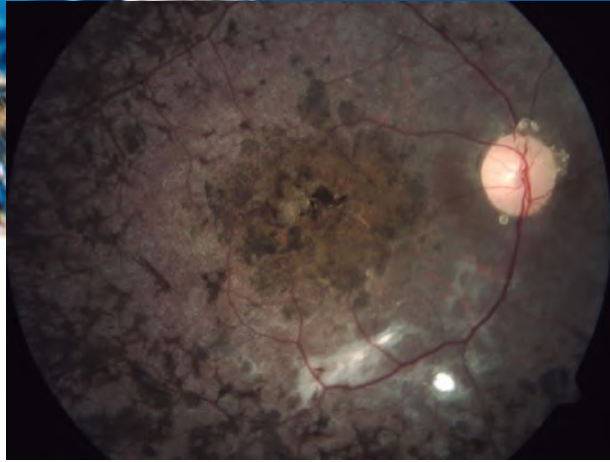
Subretinal adipose tissue-derived mesenchymal stem cell implantation in advanced stage retinitis pigmentosa: a phase I clinical safety study

Ayşe Oner^{1*}, Z. Burcin Gonen^{2,3}, Neslihan Sinim¹, Mustafa Cetin^{2,4} and Yusuf Ozkul^{2,5}

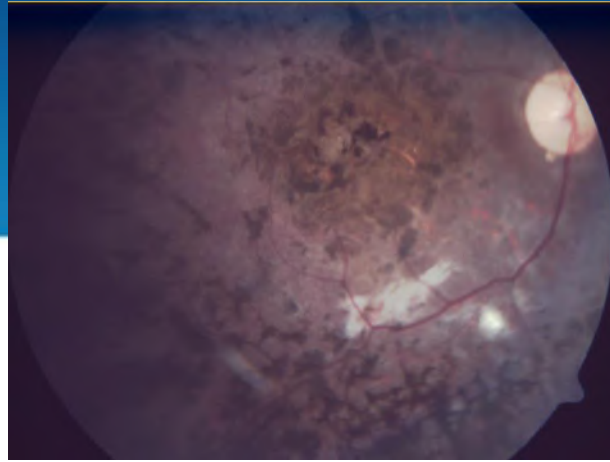
Subretinal ADMKH yapılan 14 olgunun sonuçları



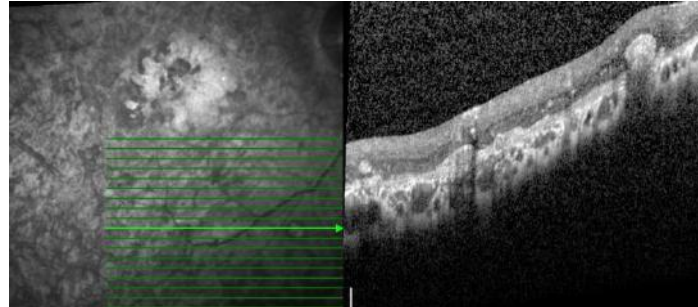
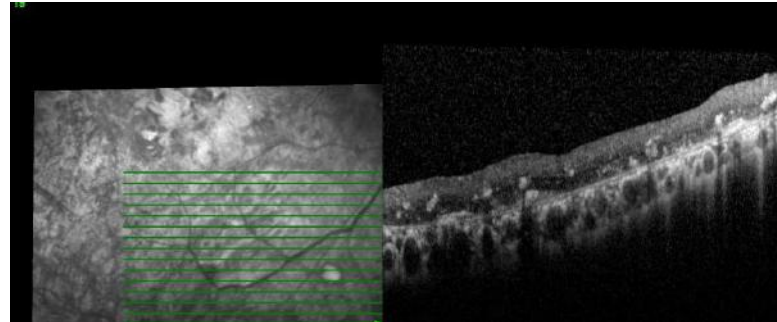
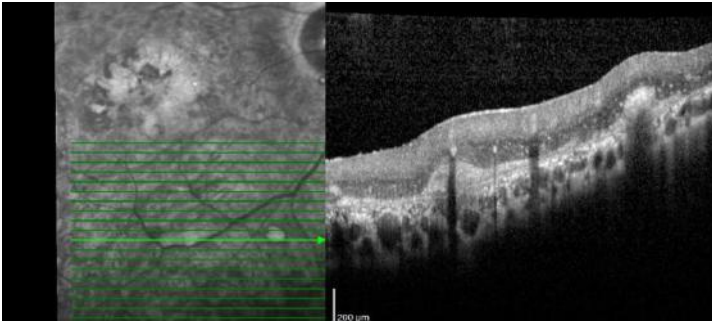
Subretinal Kk Hcre Enjeksiyonu 41 gauge subretinal kanl ile



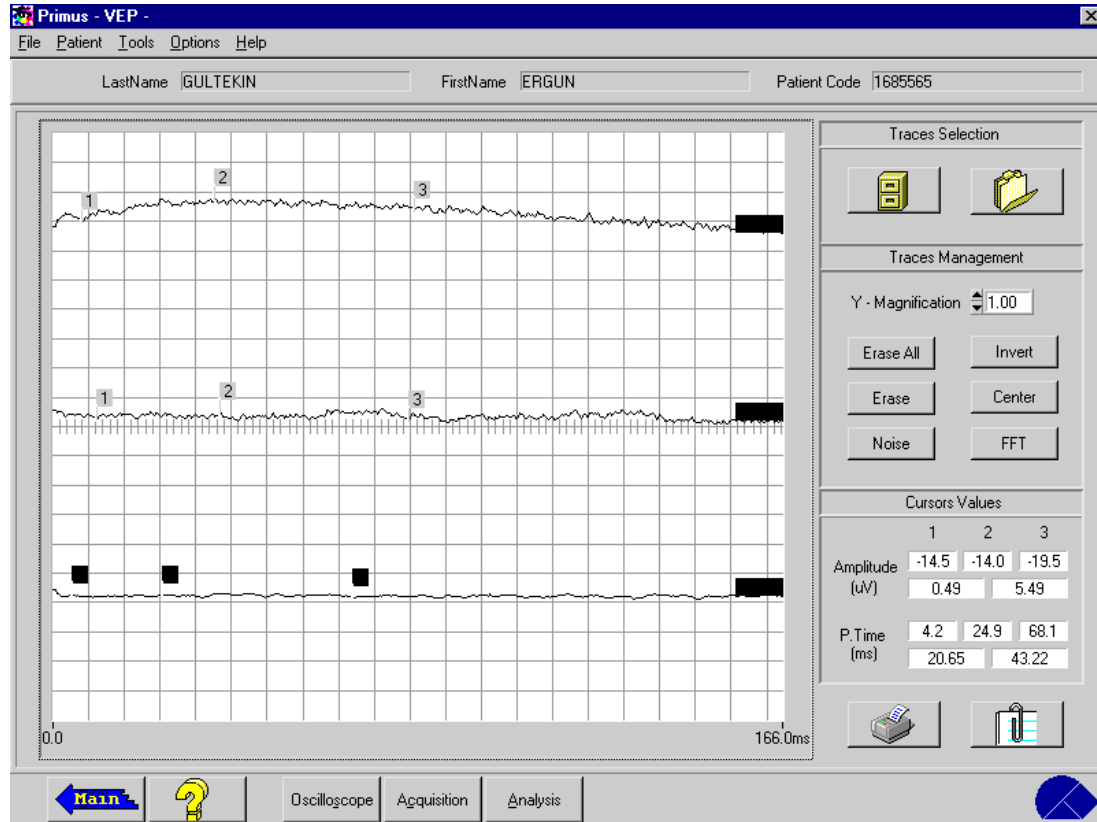
6. Ay



4 yıl



OKT takipleri



Tam alan ERG örneği



FAZ II ÇALIŞMAMIZ

- * Çalışma için kurumun etik kurulundan (No:2017/480) ayrıca T.C Sağlık Bakanlığı bünyesinde bulunan Organ Doku ve Diyaliz Hizmetleri Daire Başkanlığı'ndan (No: 56733164/203) onay alınmıştır.
- * 20 olgu opere edildi. (YBMD, Stargardt, RP, Optik atrofi)
- * GK: 0.05'in altında
- * Suprakoroidal olarak adipoz dokudan derive edilmiş allojenik mezenkimal KH kullanıldı.

Suprachoroidal Adipose Tissue-Derived Mesenchymal Stem Cell Implantation in Patients with Dry-Type Age-Related Macular Degeneration and Stargardt's Macular Dystrophy: 6-Month Follow-Up Results of a Phase 2 Study

Ayşe Oner,¹ Zeynep Burcin Gonen,^{2,3} Duygu Gülmez Sevim,⁴
Neslihan Smim Kahraman,⁴ and Metin Unlu, MD⁵


Int Ophthalmol

<https://doi.org/10.1007/s10792-019-01141-5>



ORIGINAL PAPER

Six-month results of suprachoroidal adipose tissue-derived mesenchymal stem cell implantation in patients with optic atrophy: a phase 1/2 study

Ayşe Oner  · Zeynep Burcin Gonen · Duygu Gülmez Sevim · Neslihan Sinim Kahraman · Metin Unlu




Int Ophthalmol

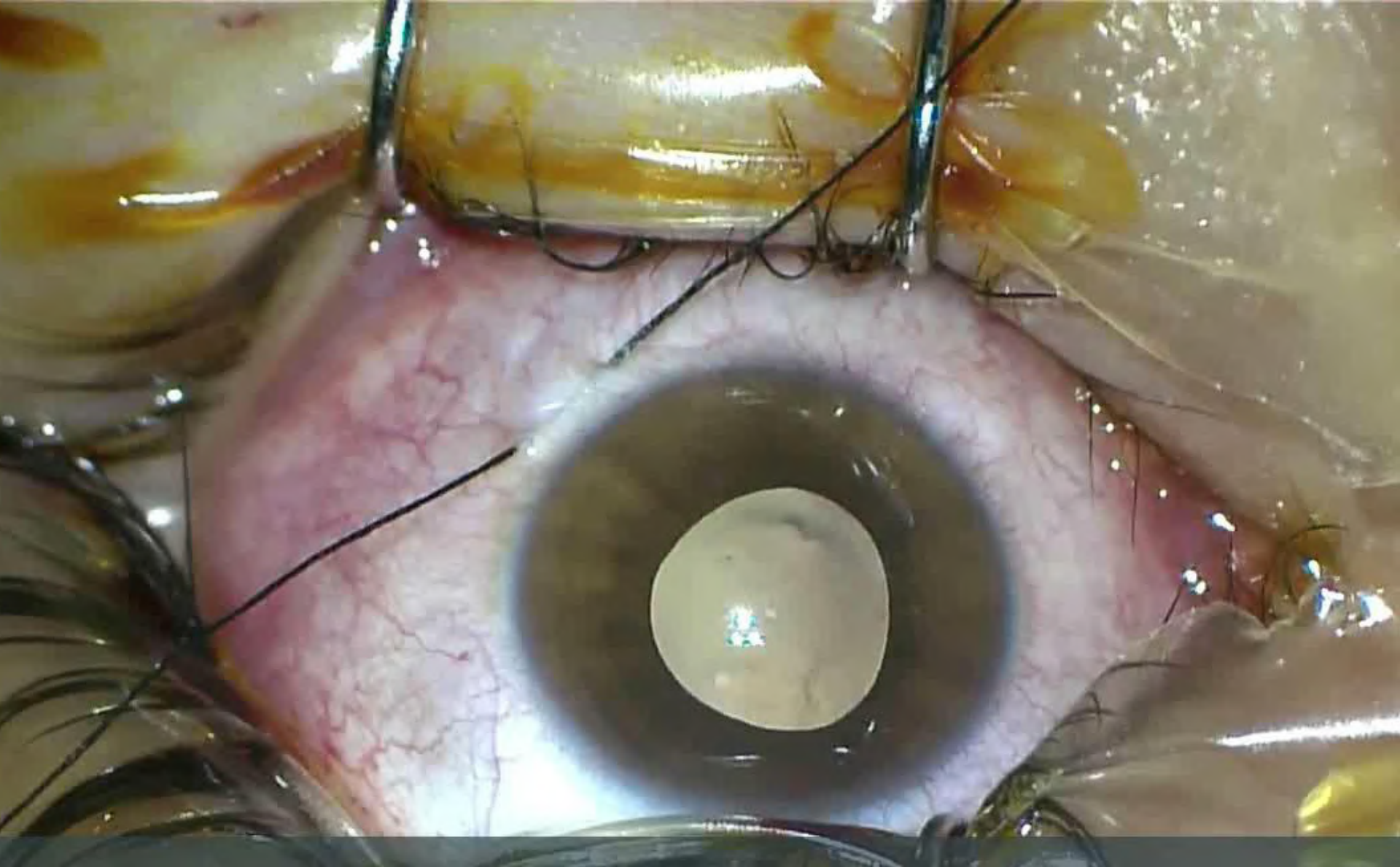
<https://doi.org/10.1007/s10792-019-01141-5>

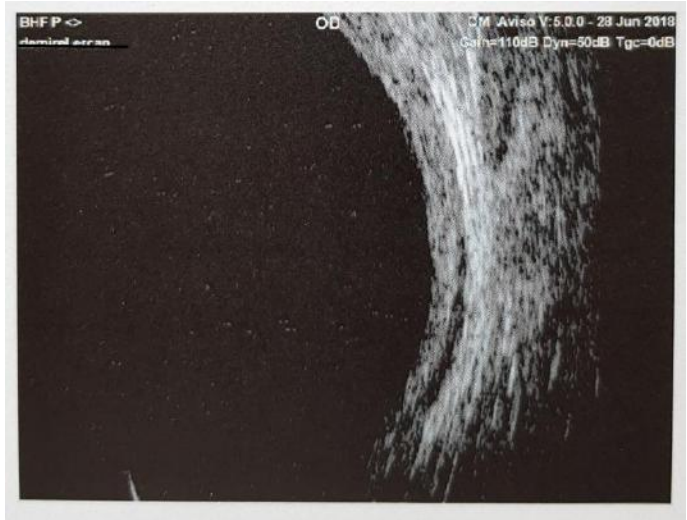
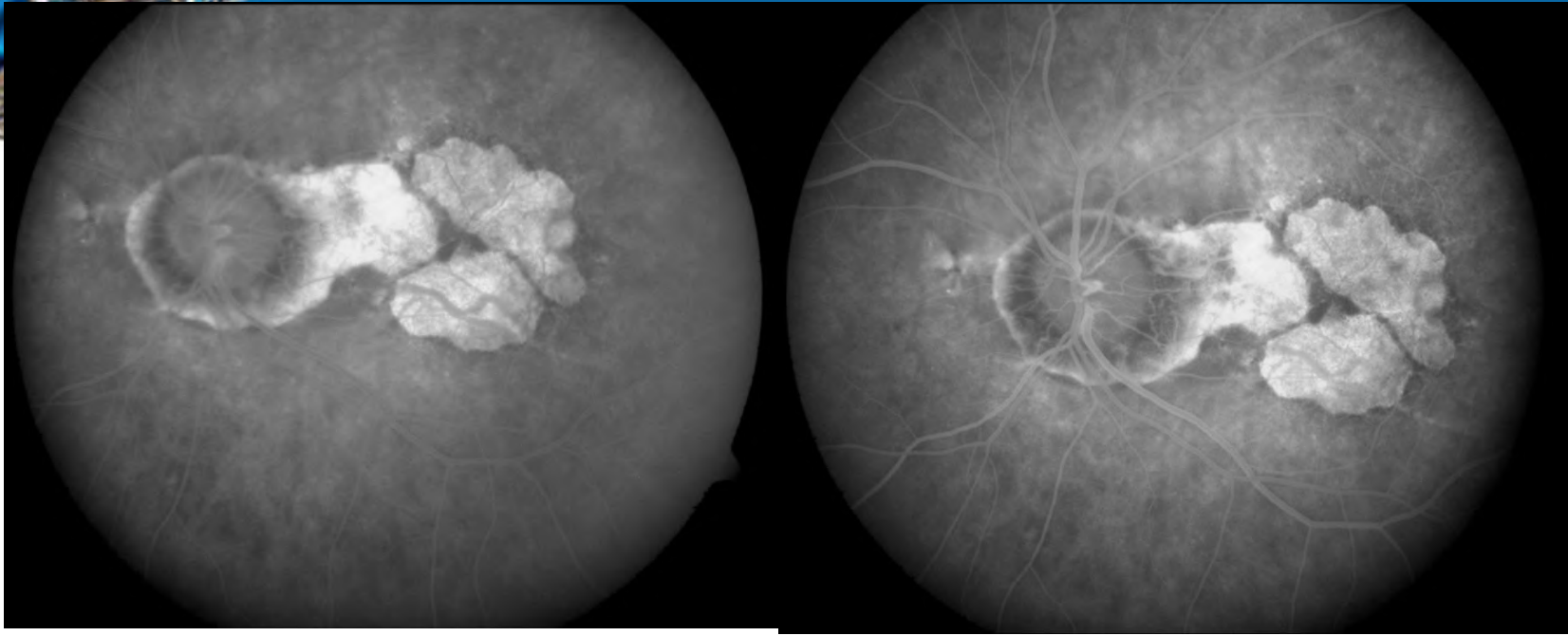
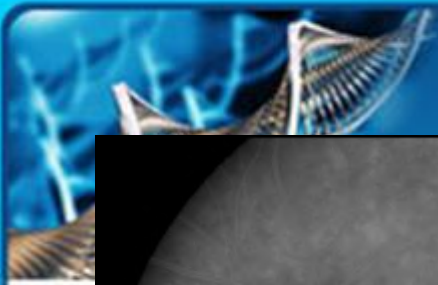


ORIGINAL PAPER

Six-month results of suprachoroidal adipose tissue-derived mesenchymal stem cell implantation in patients with optic atrophy: a phase 1/2 study

**Ayşe Oner  · Zeynep Burcin Gonen · Duygu Gülmez Sevim · Neslihan Sinim Kahraman ·
Metin Unlu**





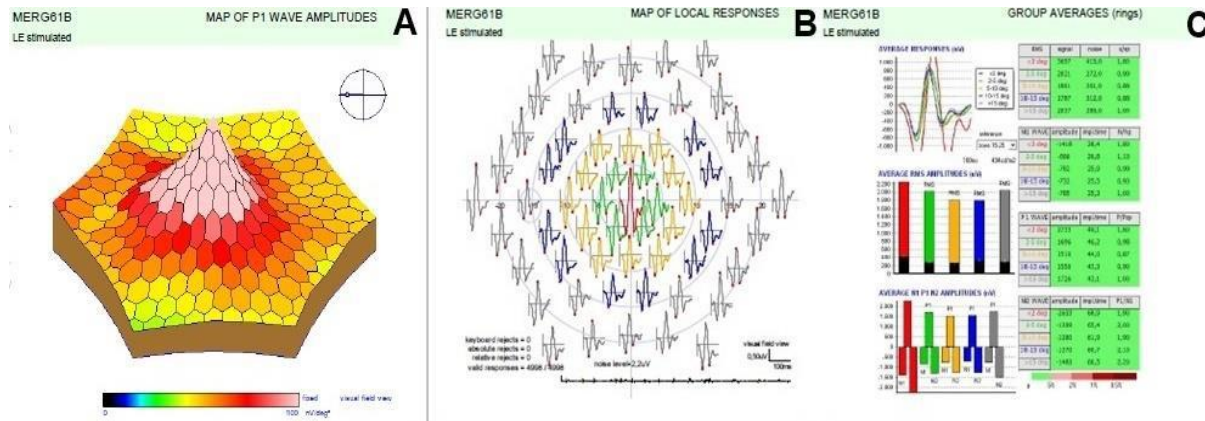


SONUÇLAR

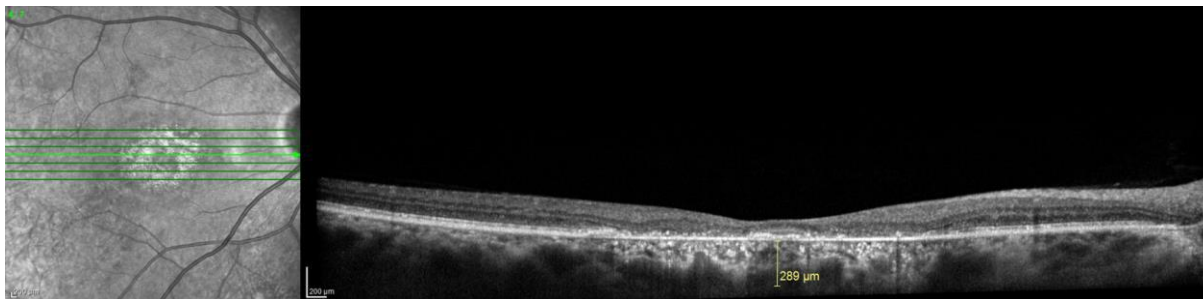
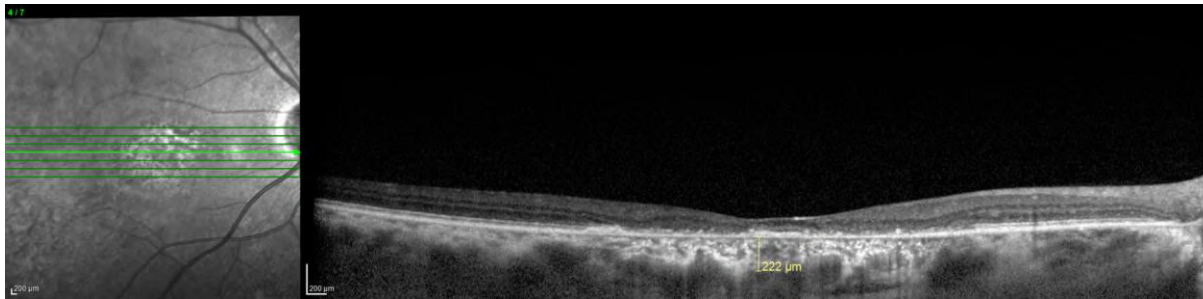
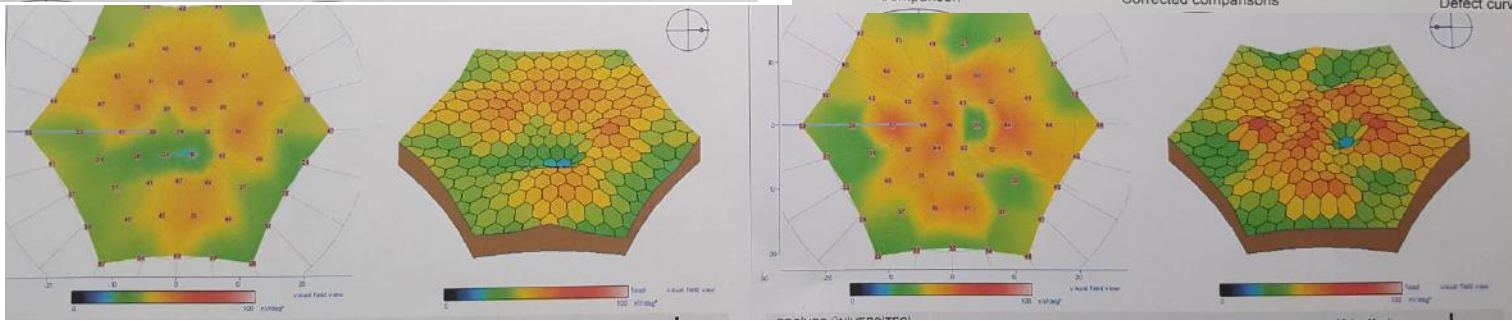
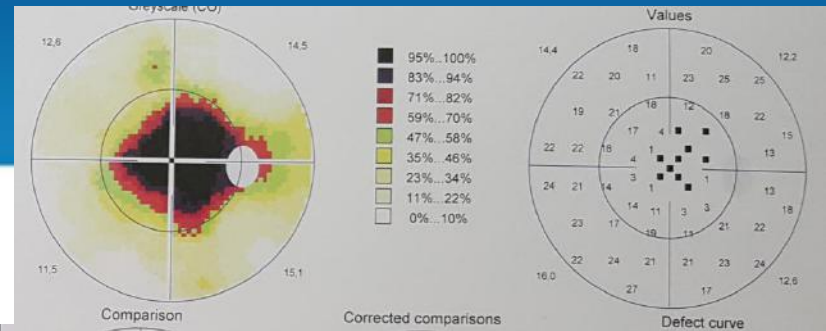
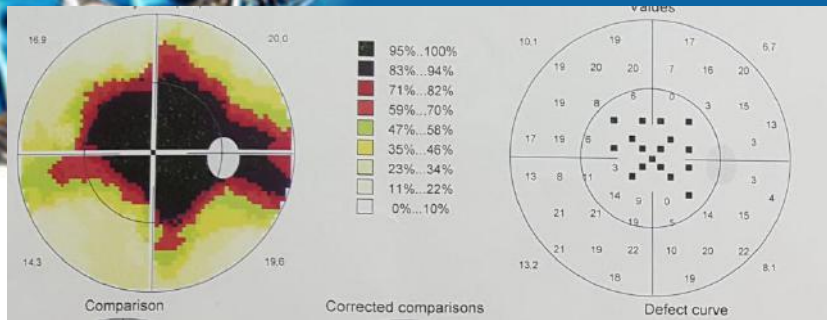
- * Hiçbir olguda sistemik komplikasyon olmadı.
- * Hiçbir olguda okuler komplikasyon yok.
- * Postop konjonktival hiperemi dışında olumsuz bulgu yok
- * Reaksiyon yok

ELEKTROFİZYOLOJİK TEST: Mf ERG

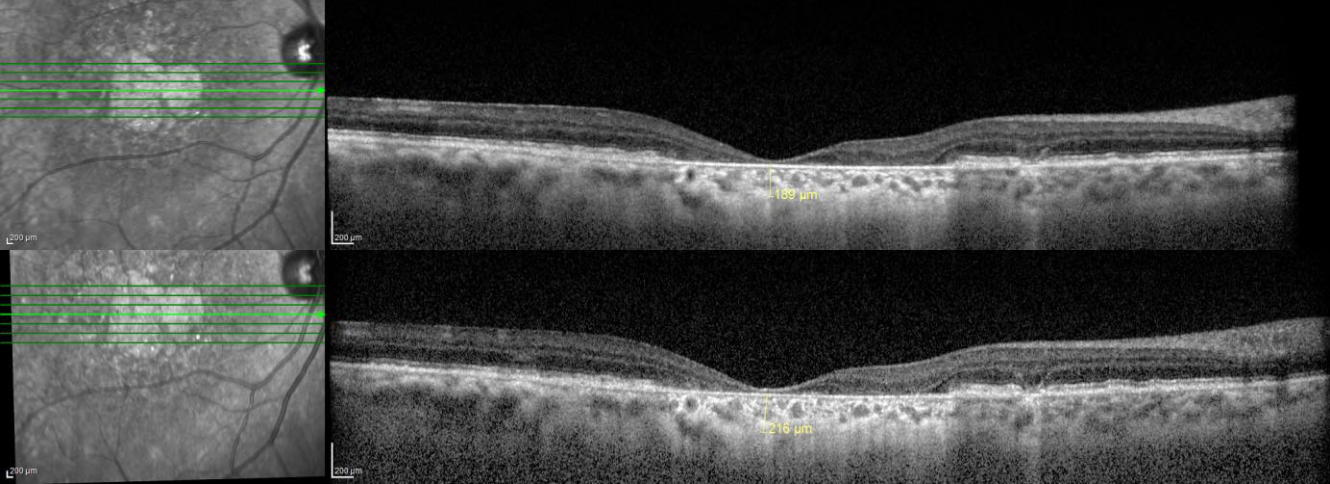
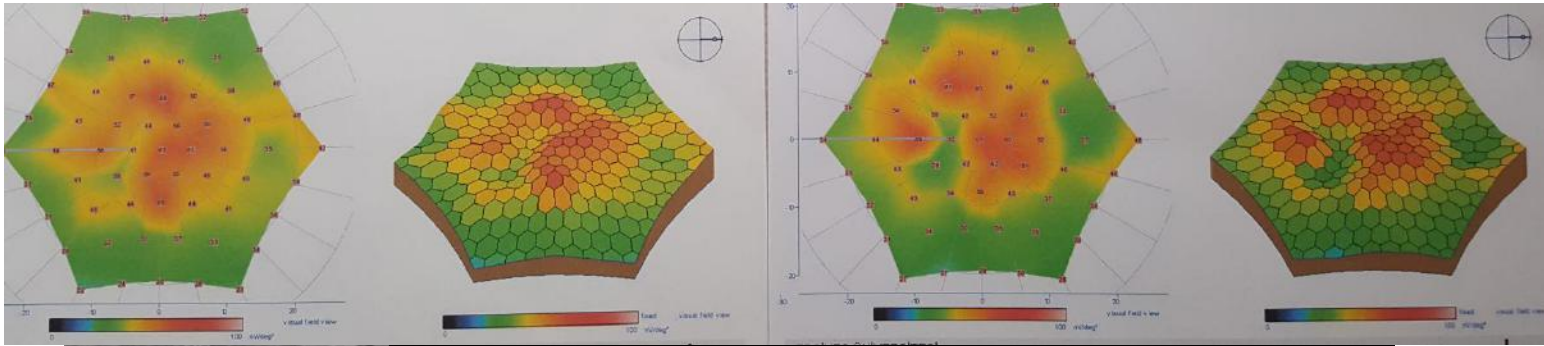
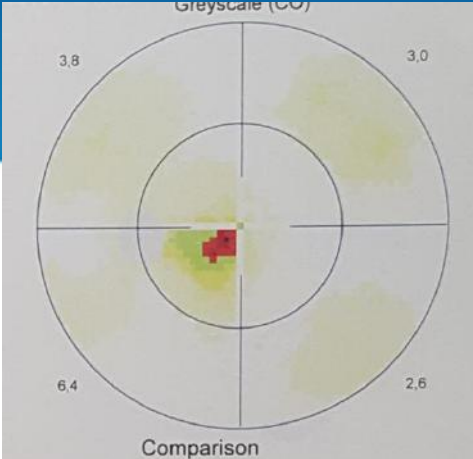
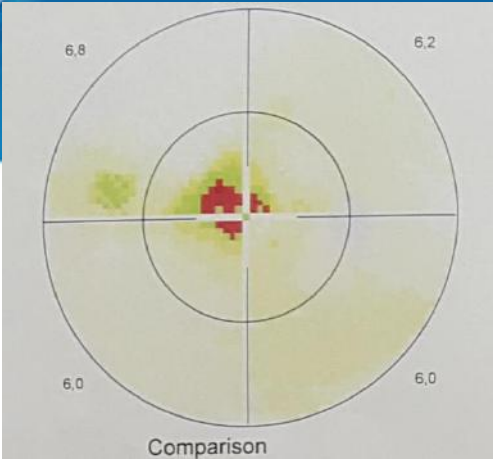
- * Mf ERG retinanın topografik elektrofizyolojik yanıtını veren bir test.
- * Hasarın olduğu bölgeyi belirlememize yardımcı olur.



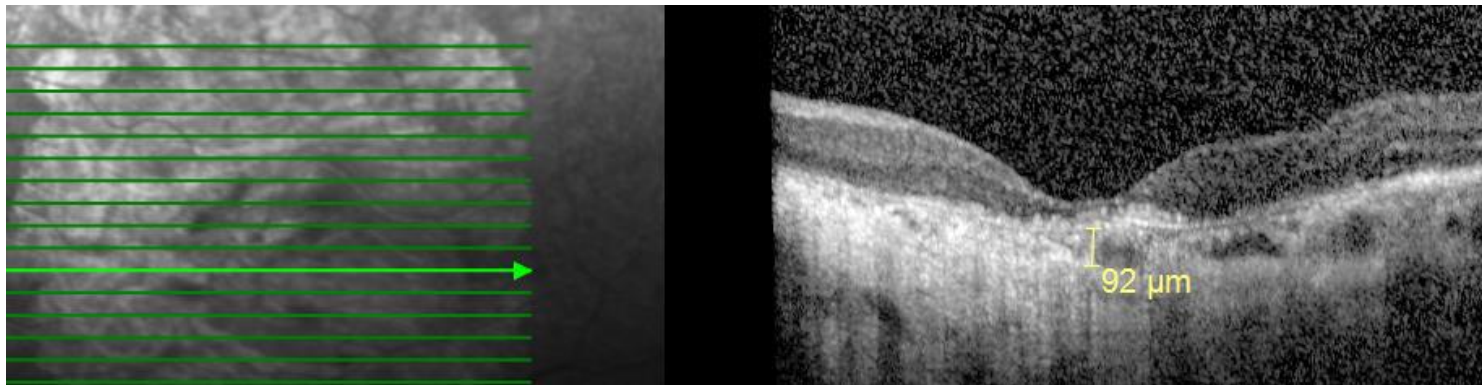
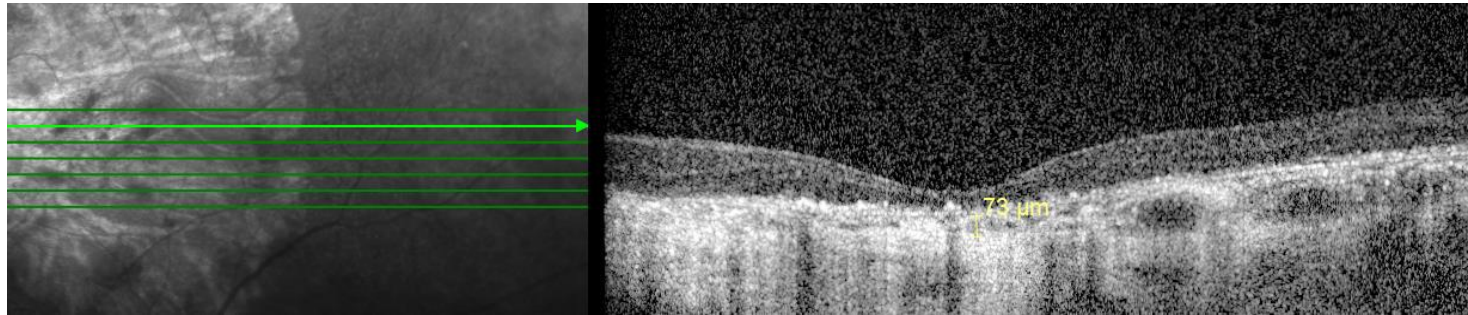
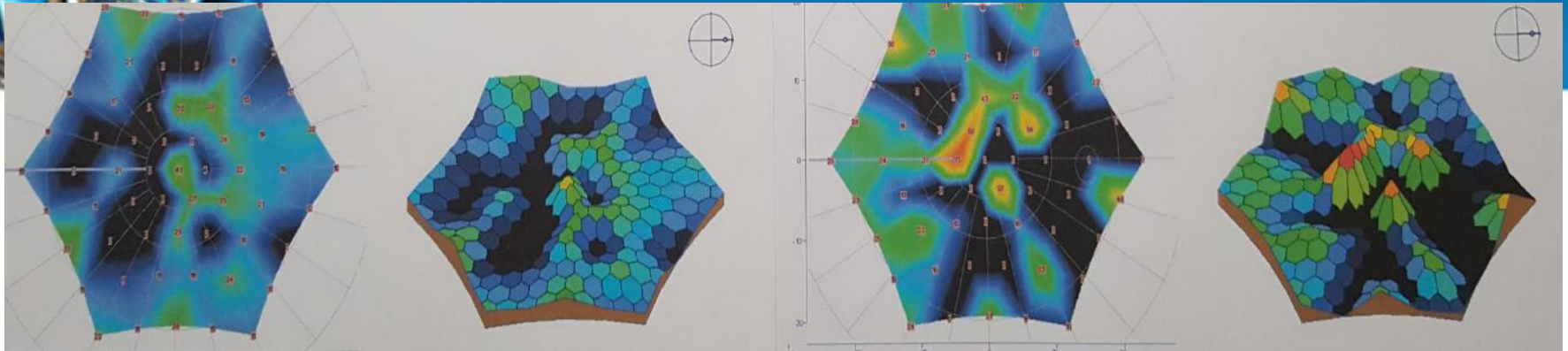
YBMD olgusu



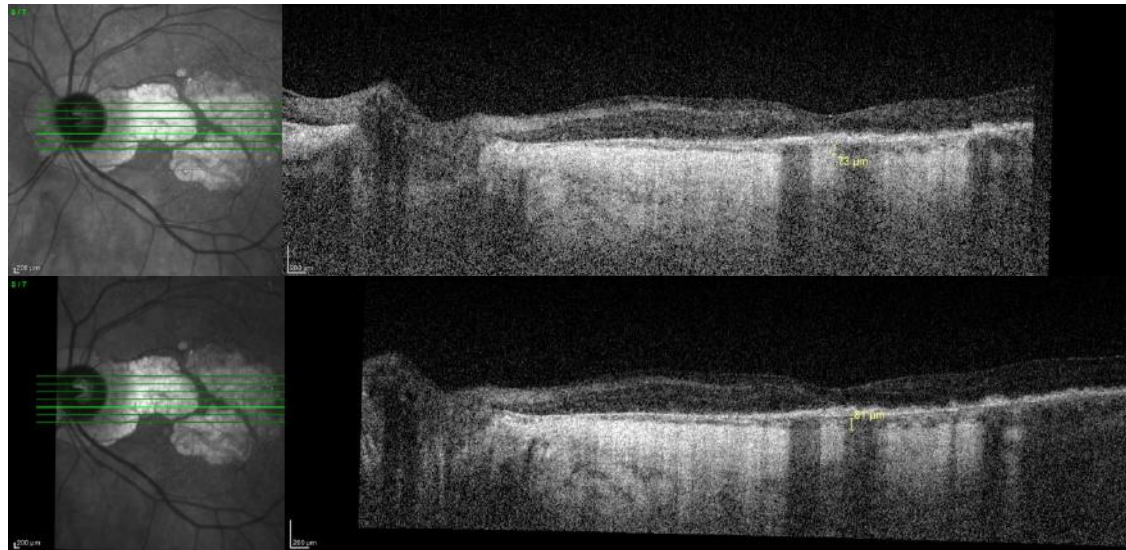
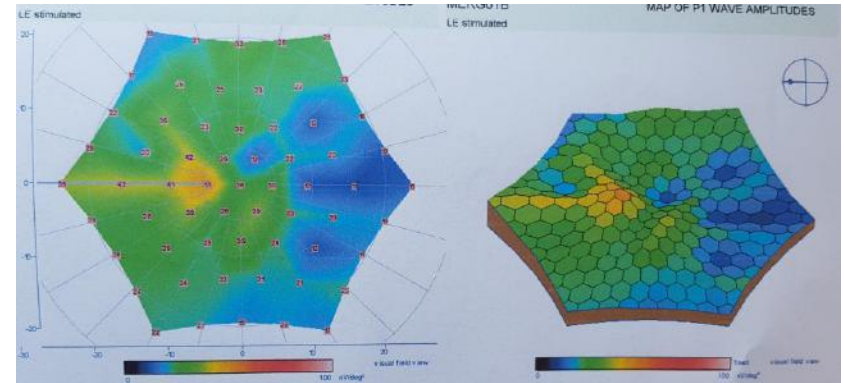
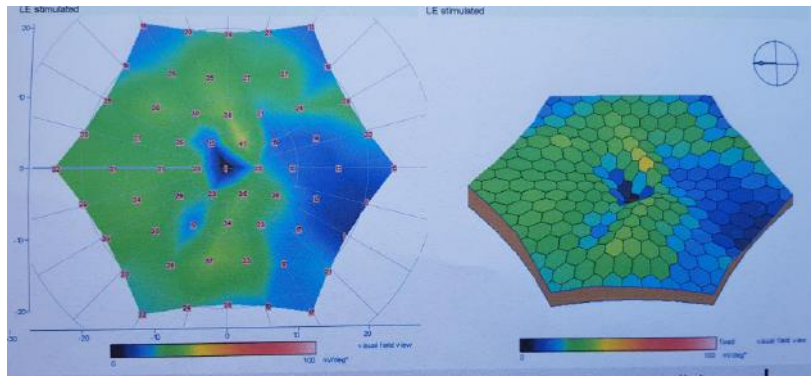
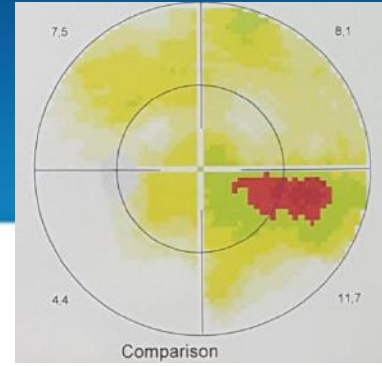
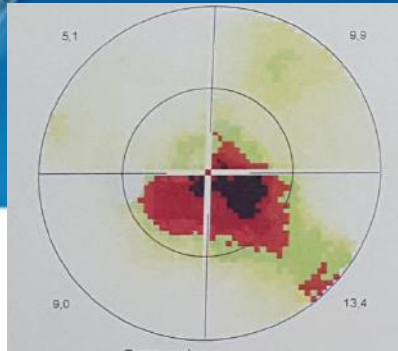
YBMD OLGUSU



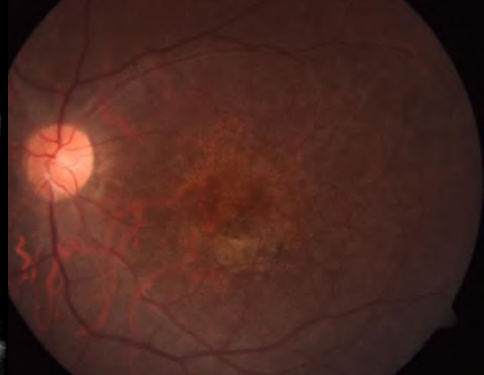
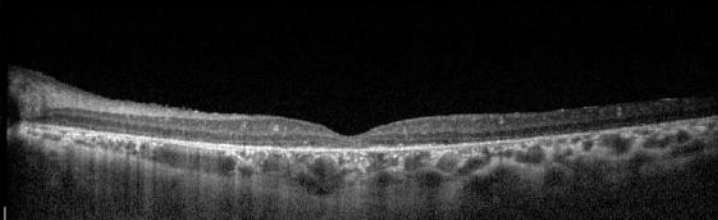
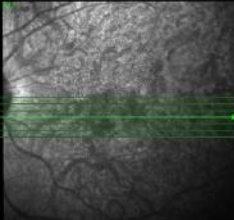
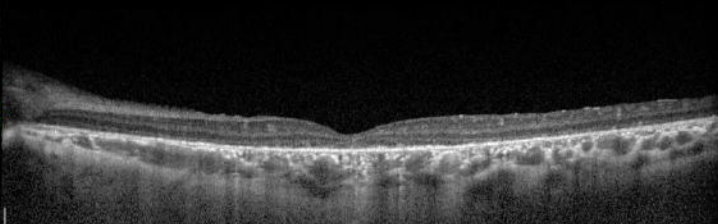
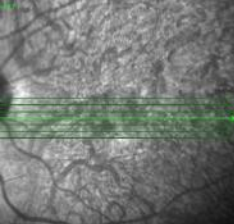
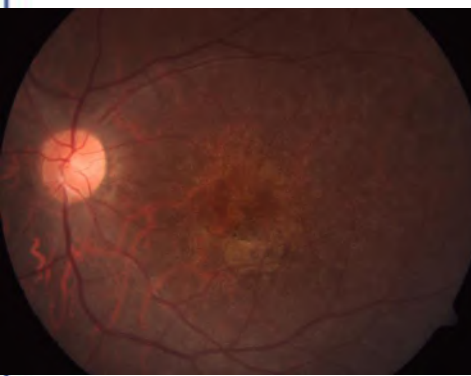
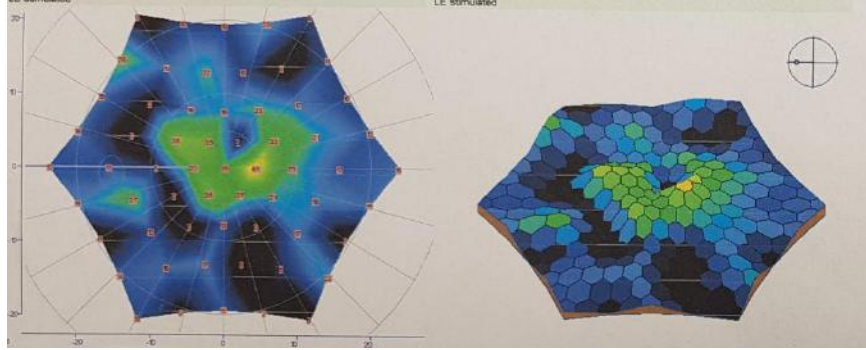
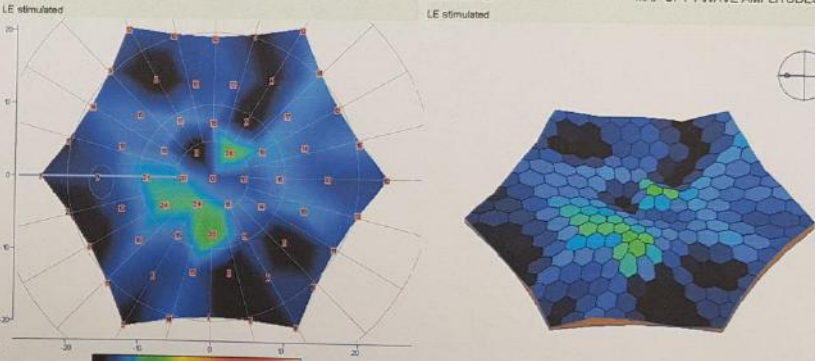
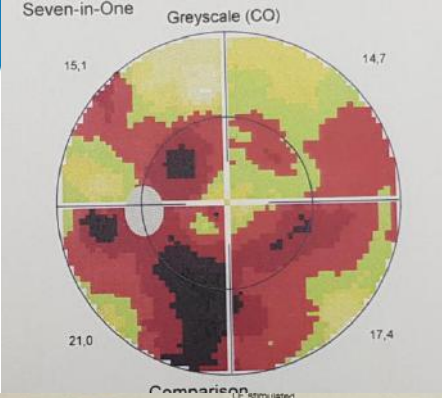
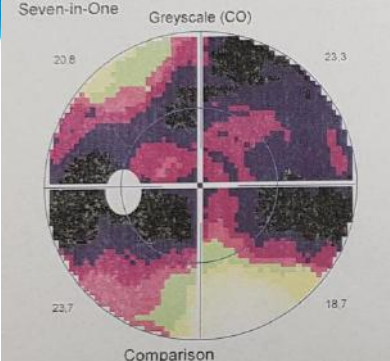
YBMD OLGUSU



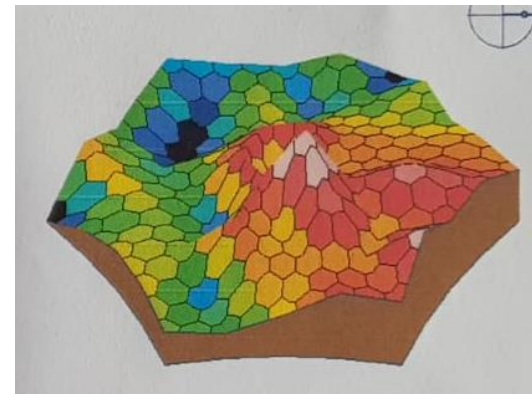


YBMD OLGUSU



STARGARDT OLGUSU



RETINITIS PIGMENTOSA





* 500 olguluk serinin onay aşamaları

tamamlanmak üzere

doktorclubawards.com

Yılın Yenilikçi Cerrahi Bilimler Doktoru Kategorisinde
Finalist olarak Desteklerinizi bekliyorum.

* TEŞEKKÜRLER